CYTOLOGY:

What every general practitioner should know (… and every future specialist)

16 April 2014
Dr C Crause
Pathologist and Senior Lecturer
Department of Anatomical Pathology

UNIVERSITEIT VAN PRETORIA
UNIVERSITY OF PRETORIA

What is cytology?

- Study of single cells
  - Pap smears
  - Sputum
  - Fluids (pleural, pericardial, ascitis and urine)
  - FNA/FNAB of preferably solid lesions
  - Please not blood, bone marrow aspirates or trephines
  - Please not chunks of tissue
- Histology
  - This is where chunks of tissue belong

Why cytology?

SAFE

- Simple
- Accurate
- Fast
- Economic

How (method in detail)

Technique of fine needle aspiration (FNA)

- The skin is cleaned with antiseptic
- The sterile 22G needle with an attached 10 or 20ml syringe is inserted into the lesion with the dominant hand while the mass is stabilised with the non-dominant hand.
- The syringe is retracted to produce and maintain a negative pressure of about 5ml.
- The needle is moved in various directions to sample cells from different areas of the mass while maintaining a negative pressure.
- When only the nub of the syringe is filled with aspirate material, the needle is withdrawn while maintaining a negative pressure until the subcutaneous tissue is reached. The piston of the syringe is then released to equalize the pressure.
- The needle is withdrawn and then completely disconnected from the syringe.
- The syringe is filled with air and reconnected to the needle.
- The material is then expressed at the frosted end of the glass slide.

Fixing the specimen on the slide

- A second glass slide is placed face down parallel to the bottom slide and both slides pulled apart in separate directions.
- One of the slides is fixed immediately using spray fixative the other slide is left to air dry. The slides should be clearly marked as to which is fixed and which is air dried.
- Please label all slides in pencil with the patients name and hospital number.
- The aerosol spray fixative must be held 17-22cm from the glass slide.
- The glass slide should be held horizontally while spraying with fixative. (If the slide is held at an angle, the material may be sprayed off the slide).
- The expiry date on the bottle of spray should be checked regularly.

Method of FNA

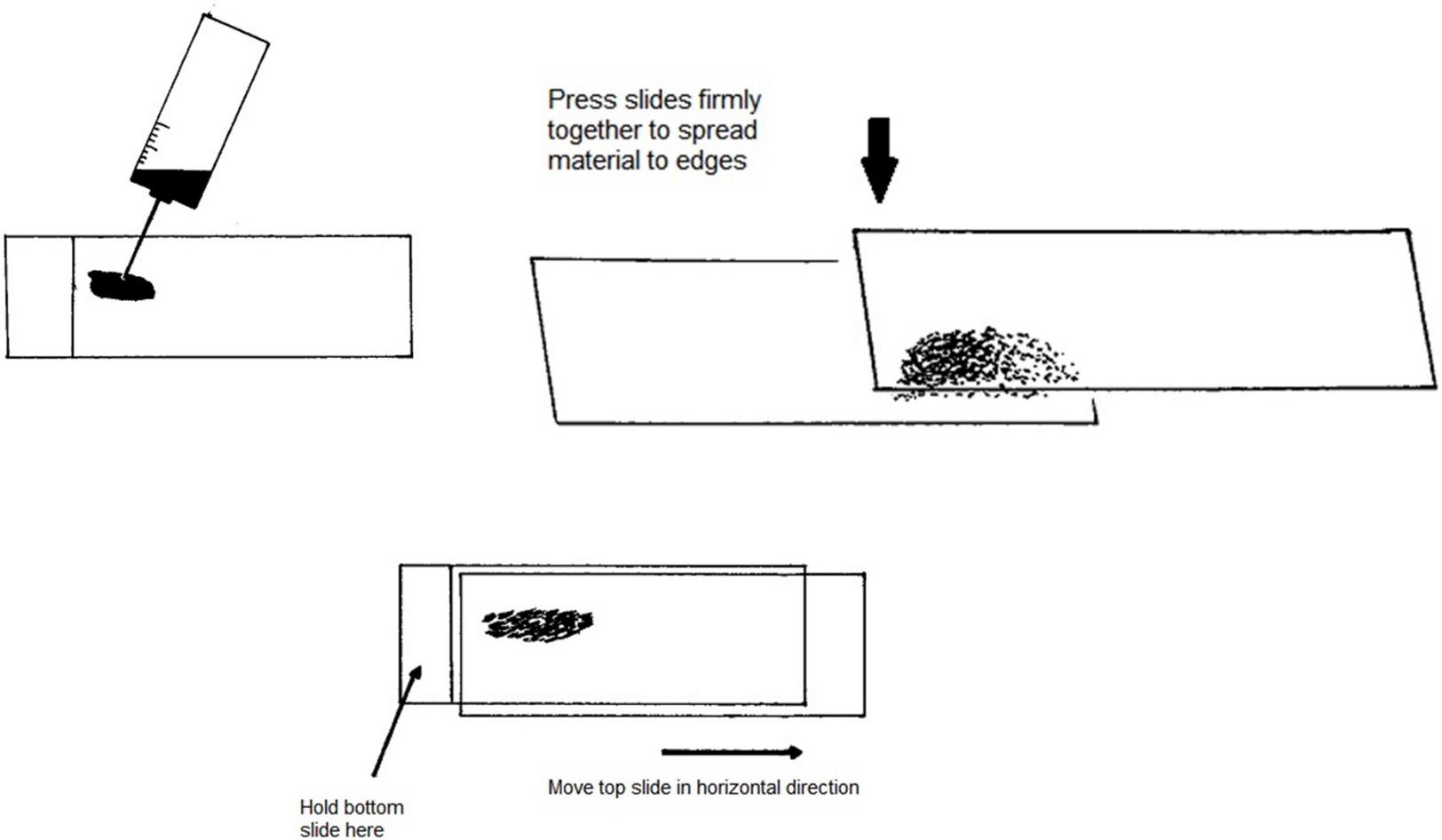

Types of specimens

- Pap smear
- FNAB/FNA

- Fluids

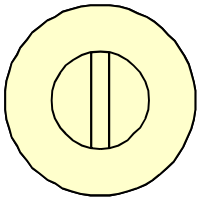

The request form

- Junk in, junk out ….
- Patient details
  - Name, surname, sex, age, hospital number
- Clinician details
  - Name, surname, MP number, telephone number
- Correct date
- Complete clinical history
  - Please keep it relevant
- Topography – where was the specimen taken from
- Any urgent specimens – please arrange with laboratory 

NATIONAL HEALTH LABORATORY SERVICE

CYTOLOGY

Practice number: 5200296

CYT1.2

FOR LAB LABELS

PLEASE PRINT IN BLOCKS AND (✓) THE APPLICABLE CIRCLES

PATIENT I.D. NUMBER :

HOSPITAL / CLINIC :

Ward : MALALANZ

Cost Centre :

NHLS Account Code :

URGENT CASES MUST BE ARRANGED WITH LAB

R
YGG01
*PK00702587
DAISY SITHOLE
61M005 04/04/2014
GYN

PATIENT INFORMATION :

Patient Hosp./ Clinic Number : SITHOLE

Fee Class

Surname : DAISY

First name : STENTUNGETU

Address : MAHLALELA

Postal Code:

Tel./Cell : 0721830764

Gender (M) (F)

D.O.B. 10/07/1983

Ethnicity (A) (B) (C) (W)

PRIVATE PATIENTS ONLY

ICD10 diagnosis codes:

Medical Aid: Plan:

Medical Aid No. Employer:

Authorisation No: Dep code:

Account to / Principal Member:

Member address:

Code

Member Tel: No. (H): (W):

Member I.D. number:

REQUESTER'S CONTACT DETAILS :

CLINICIAN (Print full name) MT S MAXMELE

Practice No :

Cell No : 0796120887 Bleep

Tel:(0) 013 79 1242

PREVIOUS CYTOLOGY

DATE / / (Y)(N)

CYTOLOGY NO: ✓

CYTOLOGY DIAGNOSIS: ✓

PREVIOUS SURGERY

DATE 2009 (Y)(N)

HOSPITAL: C/SECTION

TYPE OF:

PREVIOUS PATHOLOGY

DATE / / (Y)(N)

PATHOLOGY NO(S): ✓

SPECIMEN TYPE:

DIAGNOSIS:

RADIATION

DATE / / (Y)(N)

AREA: ✓

CHEMOTHERAPY

DATE / / (Y)(N)

TYPE:

GYNAECOLOGICAL

LMP

DATE 03/2014

CONTRACEPTION / HORMONES: (Y)(N)
i.e. IUCD, Petogen

Type:

PREGNANT WEEKS ✓

POST PARTUM WEEKS

POSTMENOPAUSAL (Y)(N) ✓

POST MENOP. BLEED (Y)(N)

Period of bleeding:

CONDITION OF CERVIX

- ○ HEALTHY
- ○ INFLAMMATORY
- ○ SUSPECTED CA

RETRO VIRUS (+) (−) (?) (Rx)

SYMPTOMATIC / DIAGNOSTIC ONLY ✗ OR

CERVICAL SCREENING PROGRAMME ✓

ORIGIN OF SMEAR

- ○ - 01 - Cervix
- ○ - 02 - Endocervix
- ○ - 04 - Vagina
- ○ - 05 - Vault
- ○ - 07 - Endometrium
- ○ - Other: Specify

SMEAR TAKEN WITH

- ○ - A4 - Smear / Spatula
- ○ - A9 - Endocervical brush / Broom
- ○ - Endometrial Endopap
- ○ - Other: Specify

NUMBER OF SMEARS

LABORATORY STAFF CODE

GENERAL CYTOLOGY

ORIGIN OF SPECIMEN / ORGAN

URINARY TRACT

- ○ - 21 - Bladder
- ○ - 22 - Kidney L/R
- ○ - 23 - Ureter L/R
- ○ - Other: Specify

RESPIRATORY

- ○ - 30 - Trachea
- ○ - 31 - Bronchus L/R
- ○ - 32 - Lung L/R (Spec)

FLUID

- ○ - 36 - Pleural L/R
- ○ - 37 - Pericardial
- ○ - 38 - Peritoneal
- ○ - 39 - CSF
- ○ - Other: Specify

AB
NG01
SG20
C/P

LYMPH NODES

- ○ - 46 - Supraclavicular L/R (P)
- ○ - 47 - Cervical (Neck) L/R
- ○ - 48 - Axillary L/R
- ○ - 49 - Inguinal L/R
- ○ - Other: Specify

HEAD AND NECK

- ○ - 55 - Mouth (Spec)
- ○ - 56 - Salivary Gland (Spec)
- ○ - 57 - Larynx
- ○ - 58 - Thyroid

GASTROINTESTINAL

- ○ - 59 - Oesophagus
- ○ - 61 - Pancreas
- ○ - 62 - Liver
- ○ - Other: Specify

BREAST

- ○ - 64 - Breast L/R
- ○ - 65 - Nipple discharge L/R

OTHER (PLEASE SPECIFY)

- ○ - 75 - Other e.g. Eye, Skin, Prostate, Hydrocoele, Testis, Ovary, Synovial, Bone, Soft tissue

CLINICAL DETAILS AND SKETCH OF LESION

REC: 16562 CHECK 1:

REG: 17118

P SCREEN: 87490

HA 90: 5843

TYPE OF SPECIMEN

- ○ - A1 - Sputum
- ○ - A2 - Urine (non-catheter)
- ○ - A3 - Urine (catheter)
- ○ -
- ○ -
- ○ -

Labelling the specimen

- Please do not put any stickers on the slides!
- Patient name, surname and hospital number or date of birth in **pencil** on the slide – “frosted area”
- Fluids – on the side on the tube / container
- Tubes:
  - Red top or specific smaller container - most fluids
  - Purple top (EDTA) – CSF
  - **No** fluids in gel (yellow) tops

Pap smears

- Papanicalou smear
- Currently in use to stain these smears
- Useful in diagnosis of:
  - Infections (HPV, HSV, CMV, Candida, TB…)
  - In situ malignancy (LSIL and HSIL)
  - Invasive malignancy (Squamous cell carcinoma)
- Please don’t wipe vigorously before taken the smear
- First pap smear then biopsy (if necessary)
- Please don’t put in the sun to dry
- Immediate fixation (spraycyte)
- Please don’t cover with another slide
- Only representative when endocervical cells present or lesion noted

Sputums

- Please ask your friendly physiotherapist for help (take after morning physio)
- Please take before breakfast
- Often multiple sputums required before final diagnosis (minimum 5)
- Please differentiate between bronchial washings and sputum
- Indications:
  - Malignancy
  - Infective conditions (Tuberculosis)

Fluids

- Ascitis, Pleural and Pericardial
- Indicate topography
- Please send immediately and mark separately for cytology
- Malignancy vs Reactive conditions

Urine

- Midstream if possible
- Catheter if known patient with cervix carcinoma
- Fresh specimen
- Indications:
  - Cystitis
  - Malignancy
  - Bilharzia

CSF

- Indication:
  - Malignancy only!!! (ALL and SRBCT/Germ cell tumours in children)
  - No cases of meningitis – microbiology/virology welcomes them with open arms!
- Separate tube (please not 5ml, 1ml is enough)
- Within 1 hour after obtaining the specimen
- Please contact the laboratory and arrange that this specimen is received and prepared in time

FNA/FNAB

- Spread evenly
- Spray immediately
- Maximum 4 slides
  - Two spray fixed
  - Two air dried
- Please don’t cover the slides
- Two sites:
  - Two separate forms (4 slides / site)
  - Breast (left and right)
  - Axilla and inguinal area

Important sites

- Salivary gland
  - Benign vs. Malignant
  - Inflammatory conditions
- Breast
  - Benign vs. Malignant
- Thyroid
  - MNG, Hyperplastic nodules, reactive conditions and lesions – benign and malignant
- Lymph node
  - Reactive, TB, malignancy (lymphoma and metastatic carcinoma)

Good sites for FNA

- Breast
- Lung
- Thyroid
- Lymph nodes
- Salivary glands

Bad sites for FNA

- Soft tissue
- Intra-abdominal organs

Ugly sites for FNA

- Skin
- Bone
- Cartilage

What happens to the specimen

- Transport
- Registration
- Prepared – laboratory technician
- Screened – cytotegnologist
- Rescreened/Reviewed – pathologist
- Diagnosis entered
- Authorized
- Available on Labtrak



NATIONAL HEALTH LABORATORY SERVICE

TSHWANE ACADEMIC LABORATORY
Tshwane Academic Division Nhls, Private Bag X323, Arcadia, GP 0007

Practice Number 5200296

FULL FINAL LABORATORY REPORT

PATIENT:
[redacted]
20/03/83 (31y) Sex F
P O BOX 1502
Marble Hall
Limpopo
Limpopo

LAB NUMBER: **MG 00798267**

Collected: 10/04/2014 13:30
Received: 11/04/2014 11:40
Printed: 15/04/2014 14:30

REPORT TO:
Dr M.S. SANDAMELA
SUG6 General Surgery Clinic
Steve Biko Academic Hospital
Private Bag X169
Pretoria
Gauteng
0001

Patient Location: Steve Biko Academic Hospital, SUG6 General Surgery Clinic
Hospital Number: **GP54244968**
FOR ENQUIRIES AND FOLLOW-UP TESTS, PLEASE QUOTE PATIENT'S MRN NUMBER MRN31936297

DEPARTMENT OF ANATOMICAL PATHOLOGY

Tel: 012 319 2333, Fax: 012 319 2458

Specimen received: Parotid mass aspiration, right (Parotid area, right)
Tests requested: Fine needle aspiration

CYTOPATHOLOGY REPORT

Cytology Number: MGYN/14-24870-A
Clinical history: A 31 year old patient presented with bilateral parotid enlargement of which the right side is cystic.

FINAL DIAGNOSIS:
A monomorphic pattern of lymphocytes present. A lymphoproliferative lesion cannot be excluded. Recommend biopsy if clinically indicated.

ADDITIONAL FINDINGS:
A monomorphic pattern of lymphocytes, ductal epithelial cells and blood present.

RECOMMENDATION:
Recommend biopsy if clinically indicated.

REPORTED BY:
Miliswa Mtukulu

AUTHORISED ON BEHALF OF:
Dr Paula Eyal

Authorised by: N Heunis (Medical Technologist) Fine needle aspiration

-- End of Laboratory Report --

Poor quality

- No cells
- Only blood
- Degenerated
- Crush artifact
- Too thick
- The lesion was missed

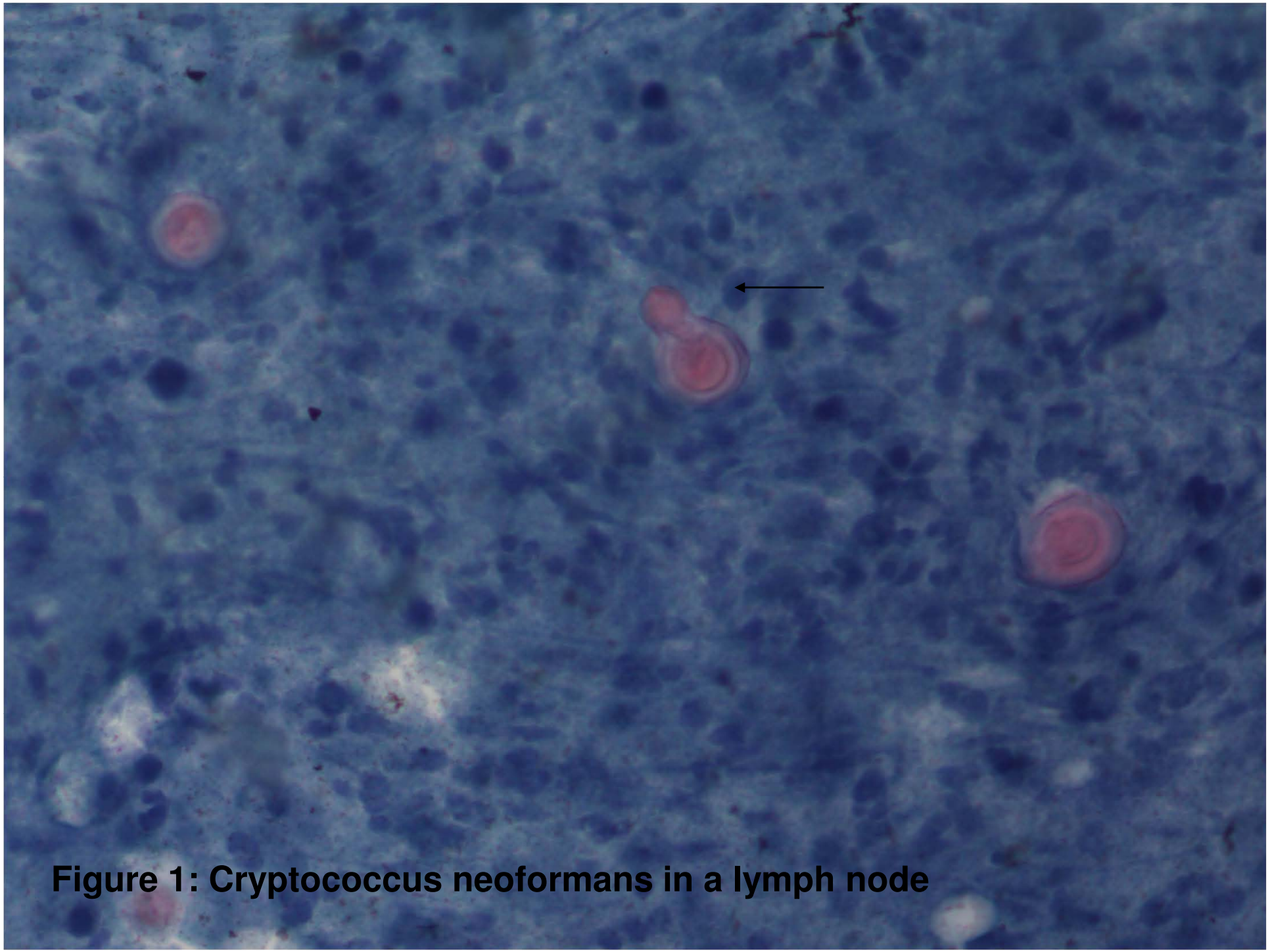

Figure 1: Cryptococcus neoformans in a lymph node

Figure 2: Cryptococcus neoformans on CSF

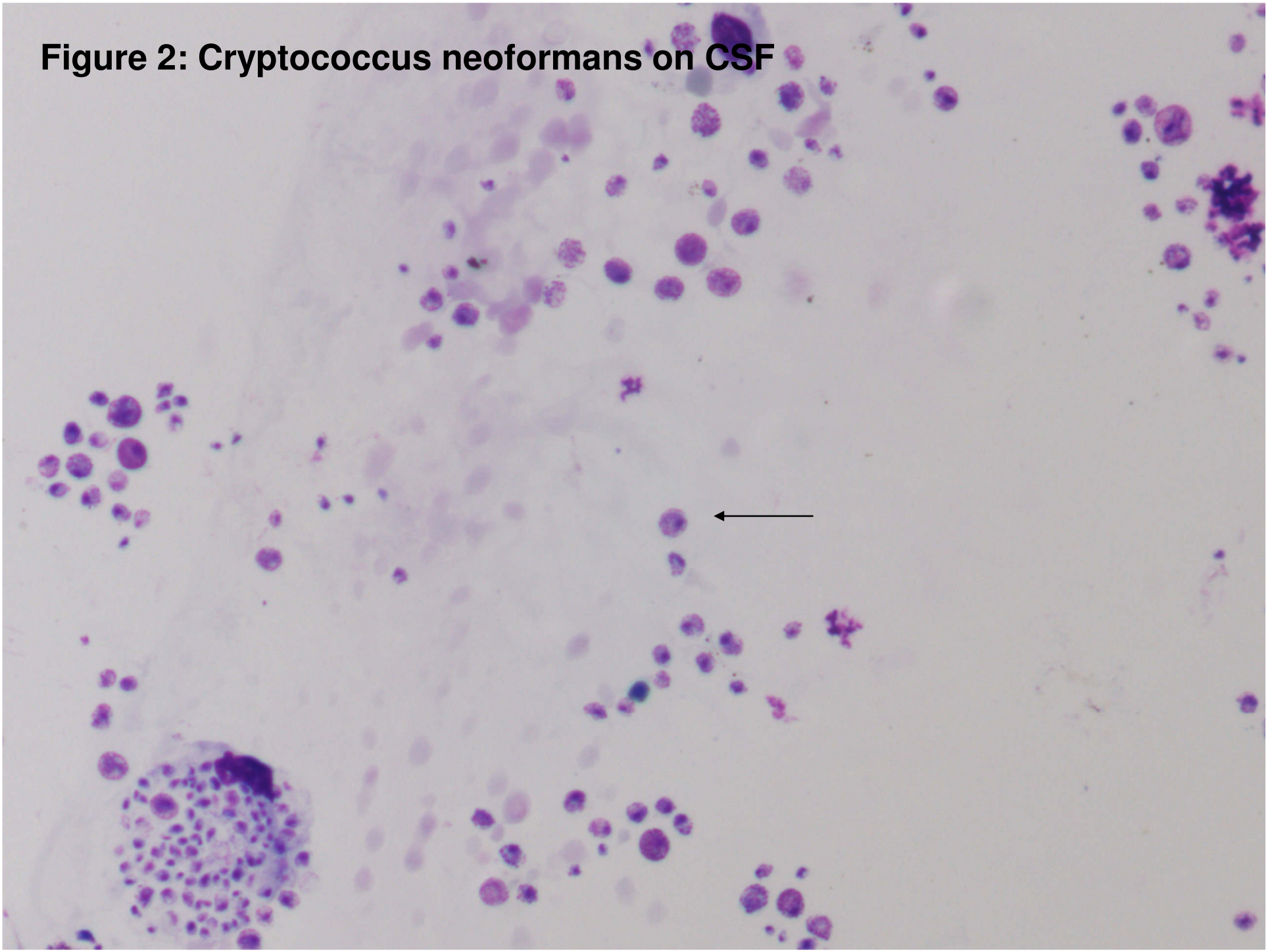

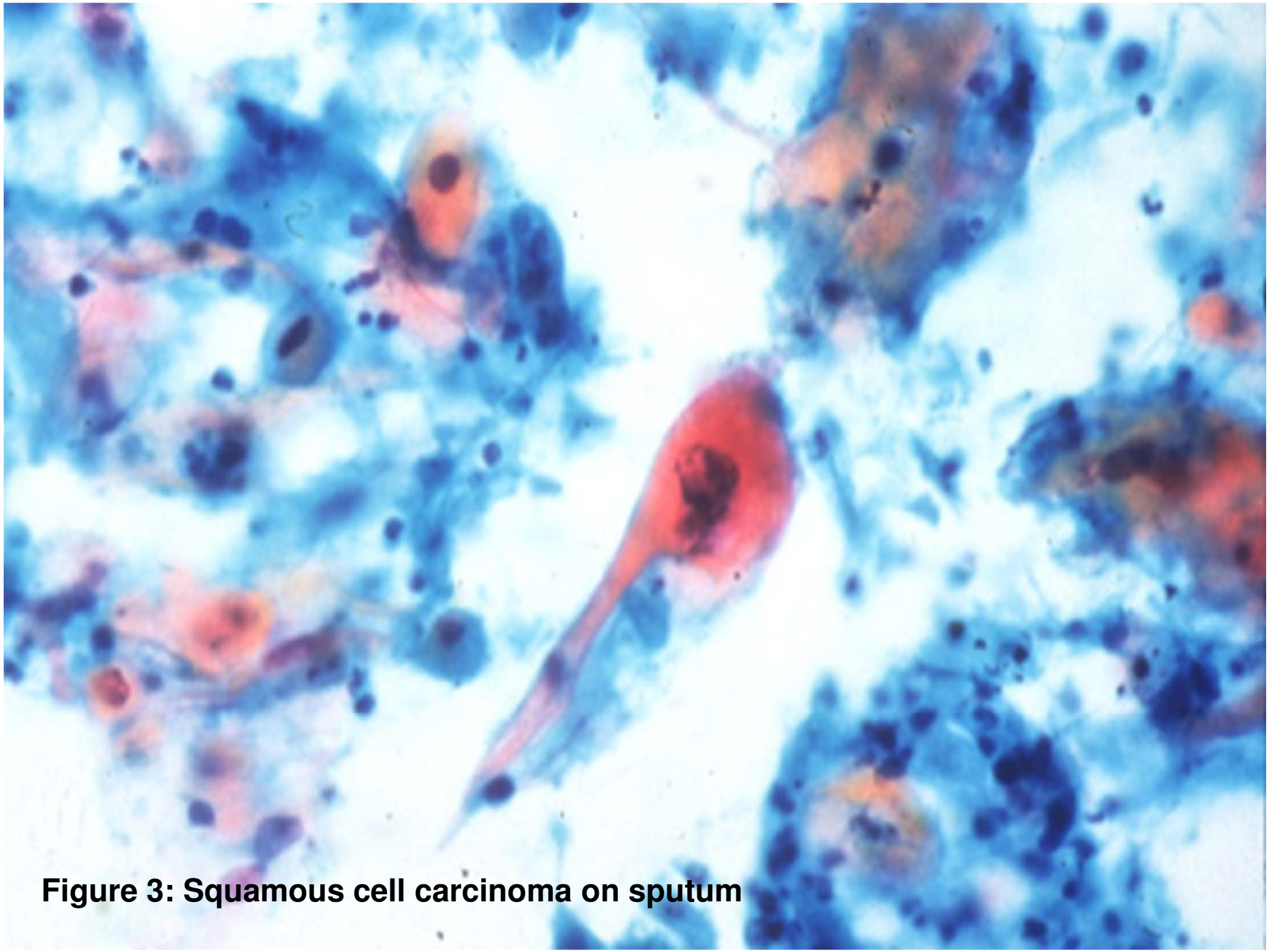

Figure 3: Squamous cell carcinoma on sputum

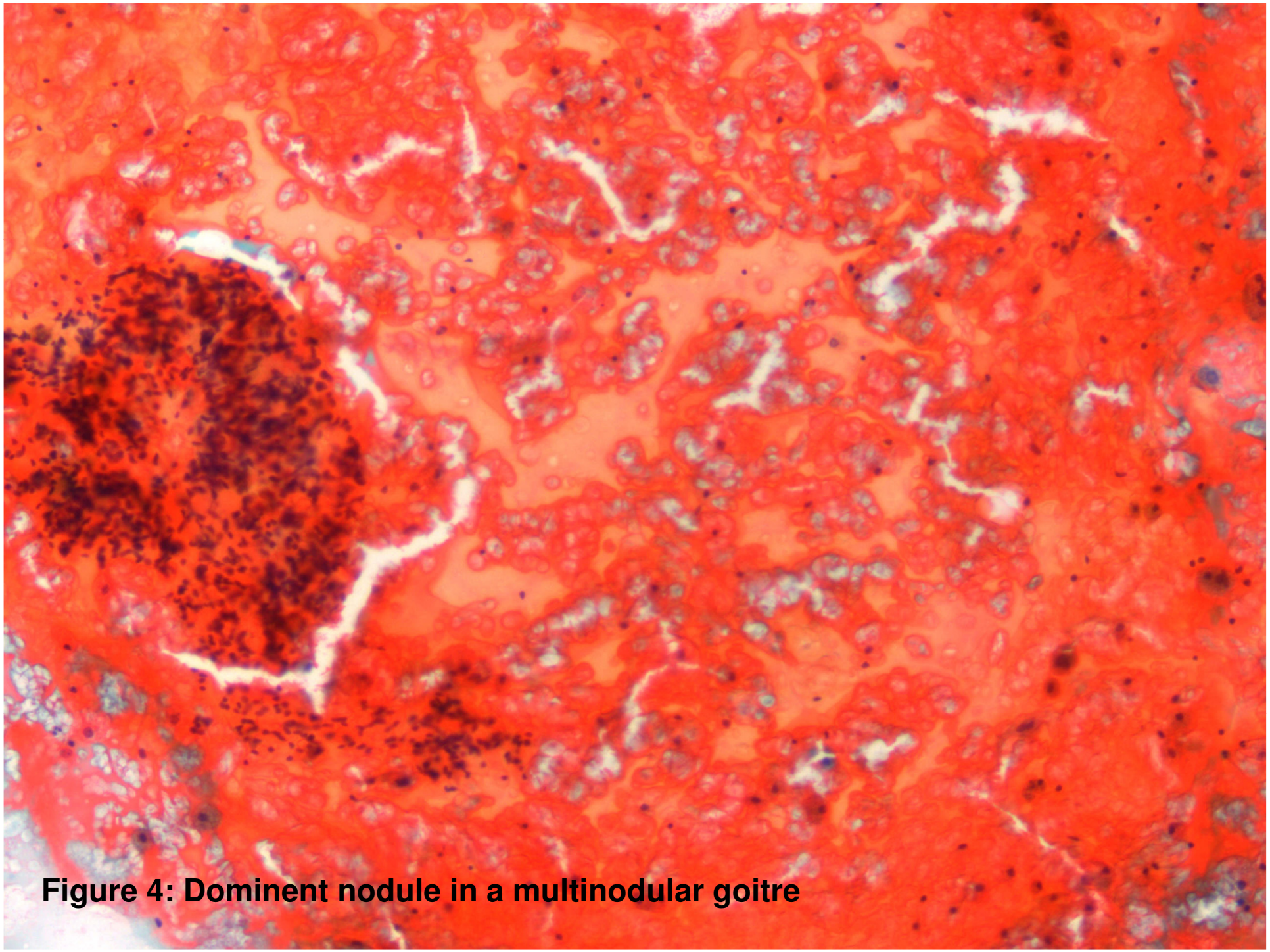

Figure 4: Dominent nodule in a multinodular goitre

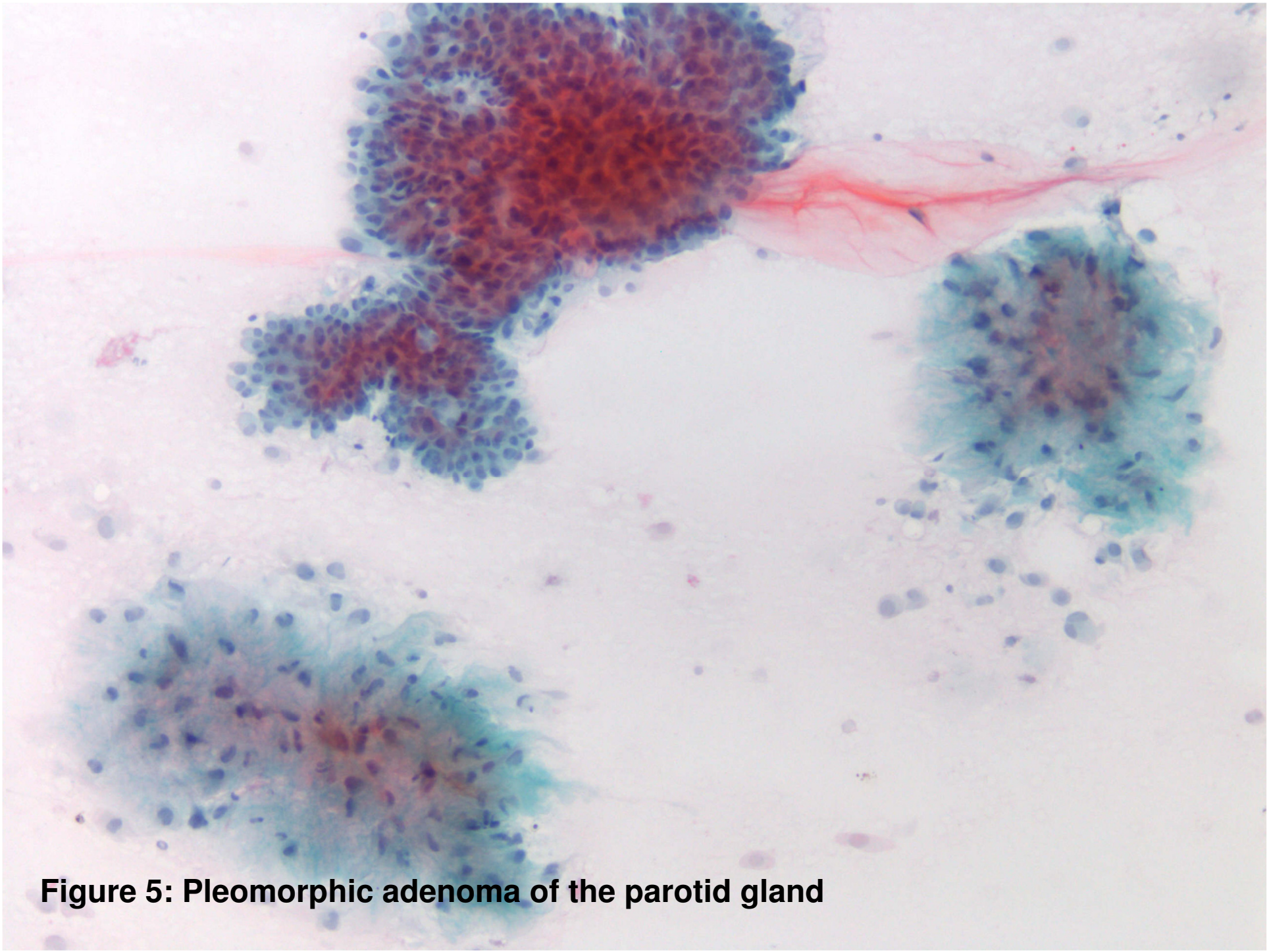

Figure 5: Pleomorphic adenoma of the parotid gland

Liquid based cytology
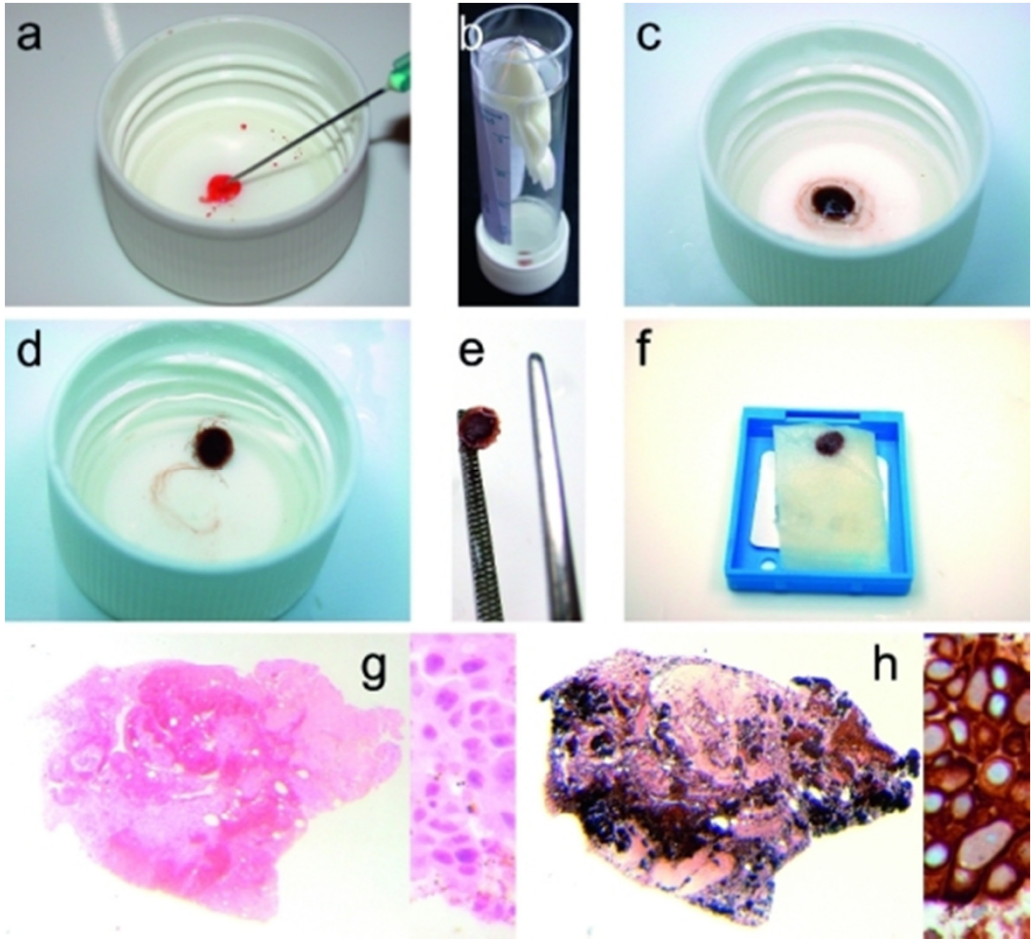
Cell blocks