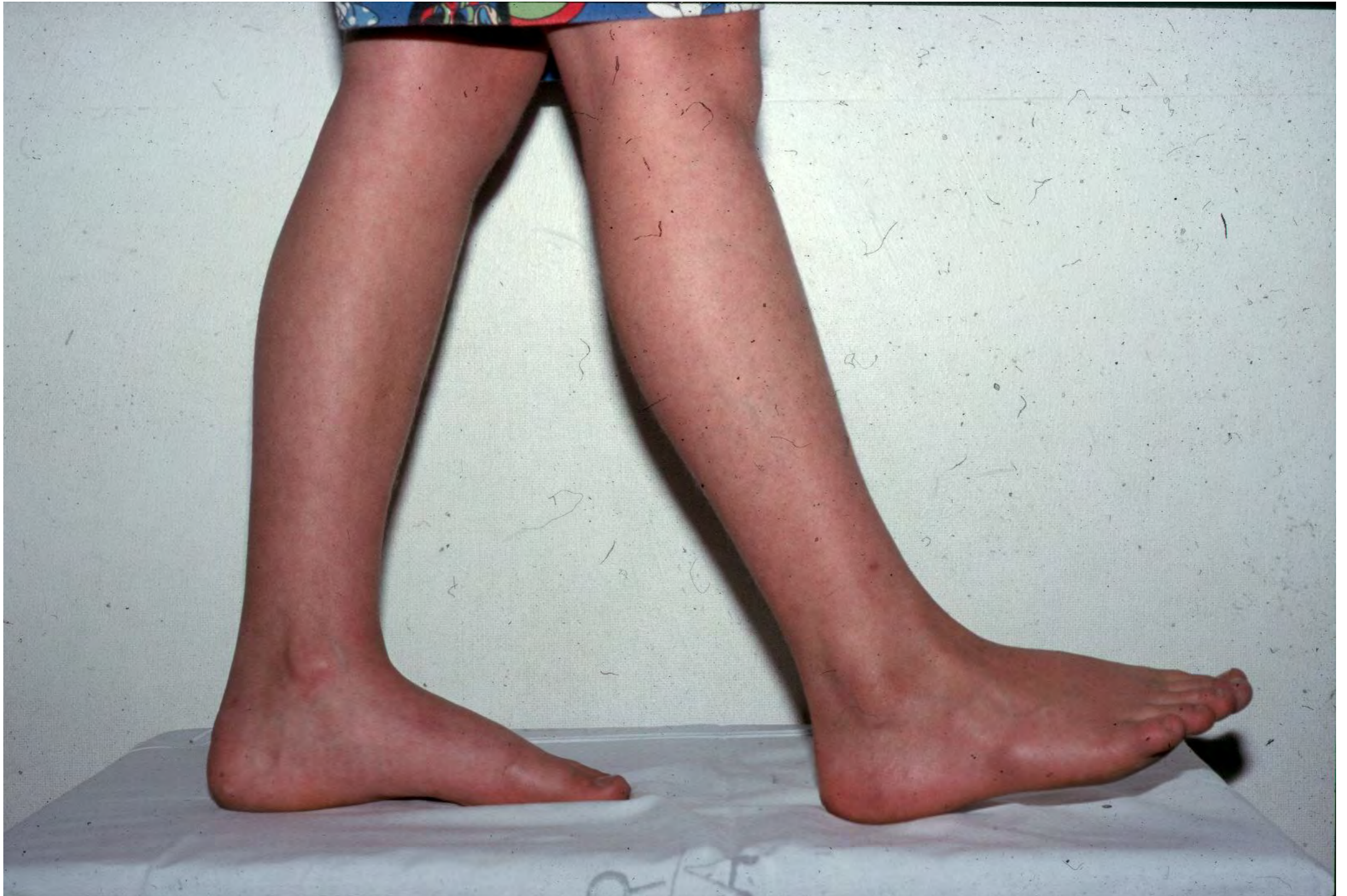

Clinical examination of the foot 2012

History

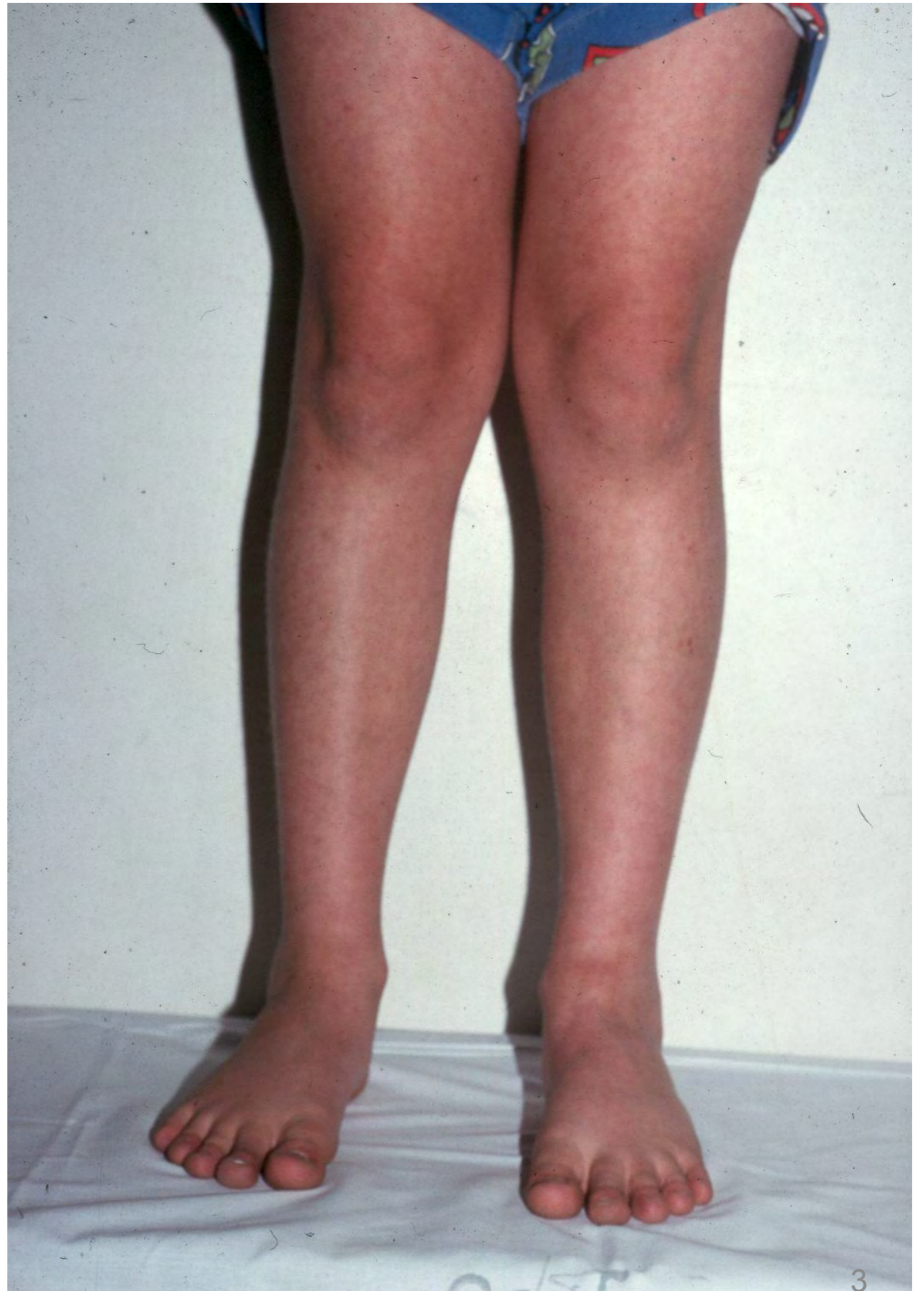- **Ask:**
- **Where do you have pain?**

WALKING

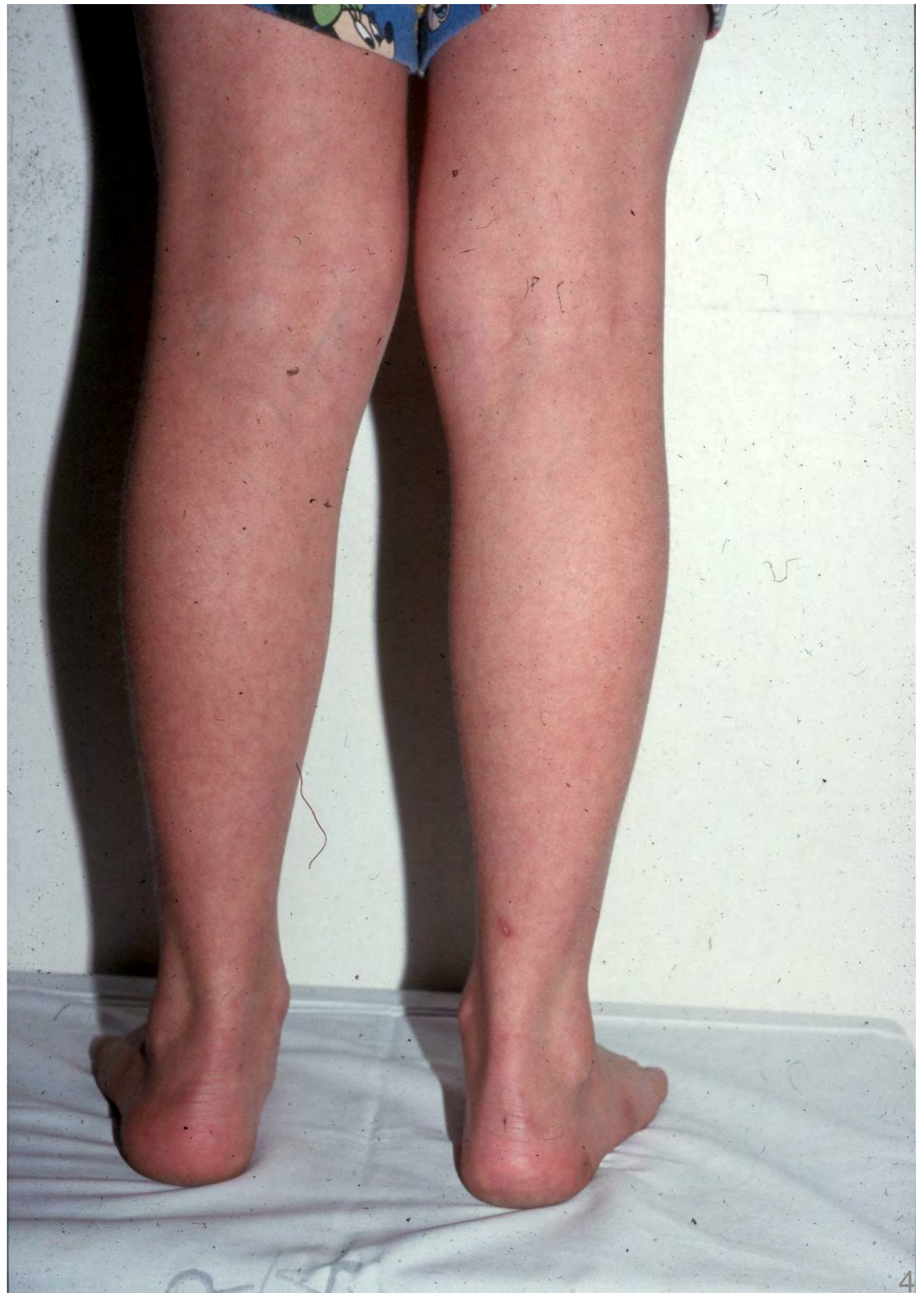

**Alignment of
knees**

**Alignment of
hind foot**

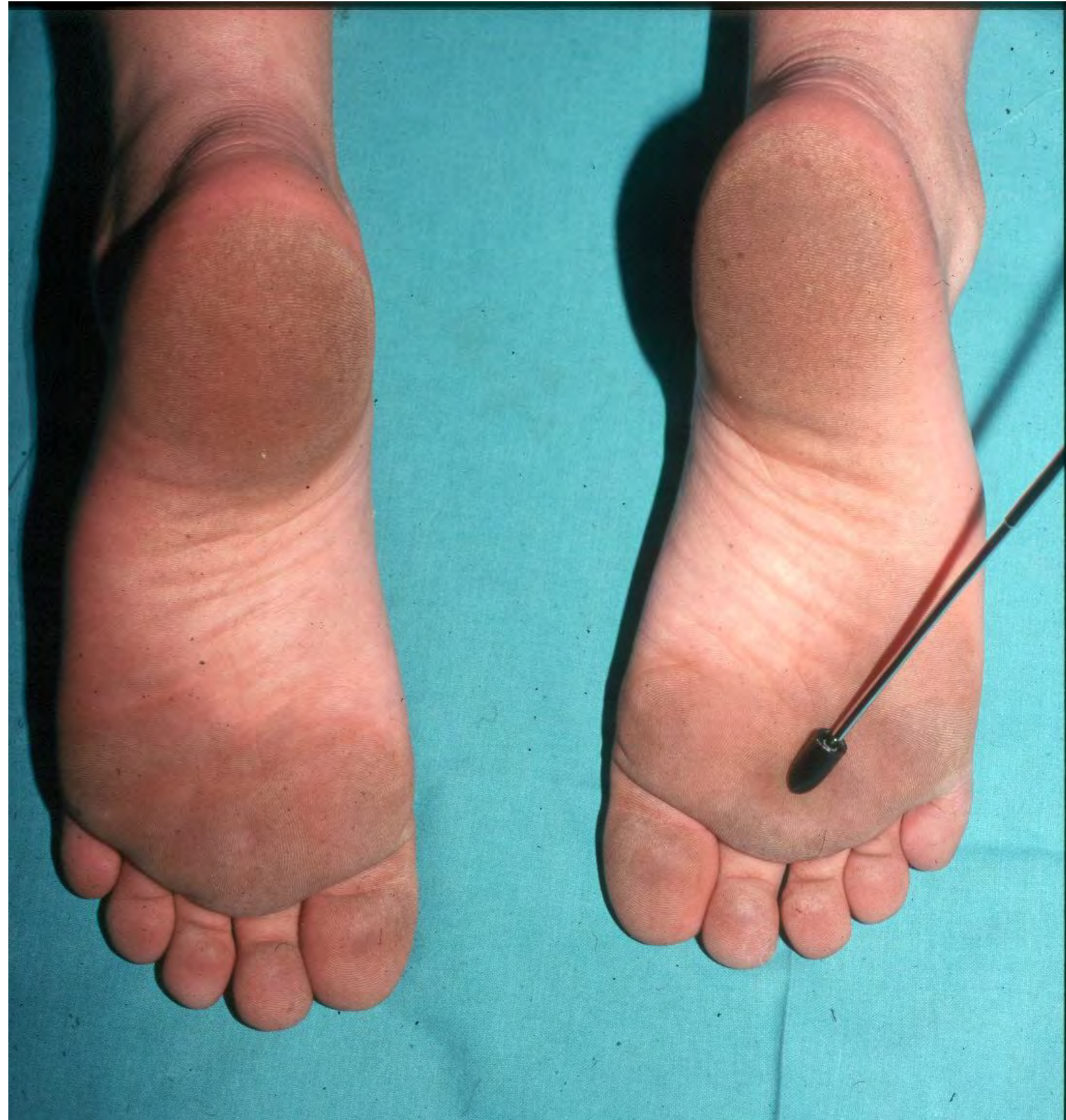

Alignment of hind foot

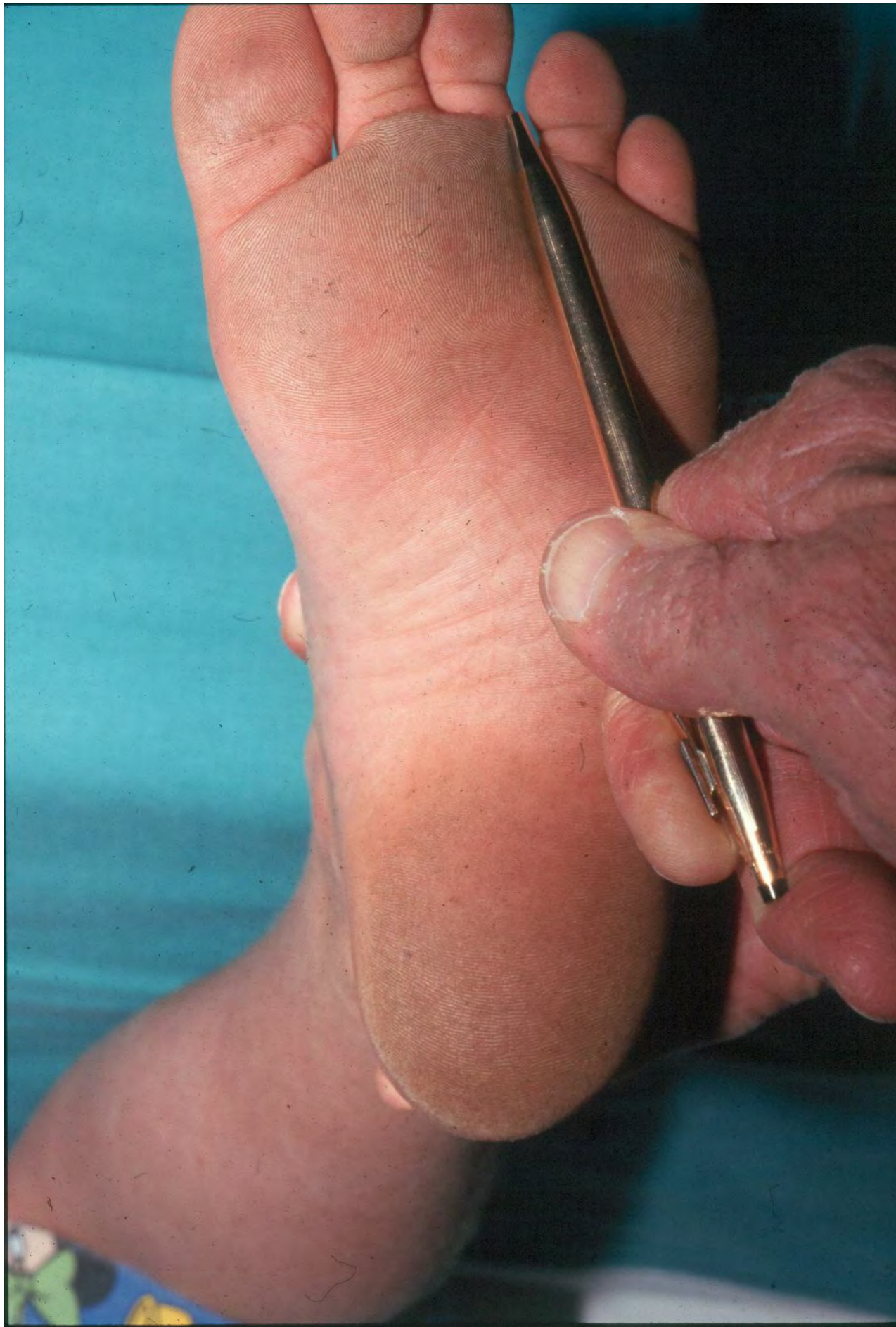


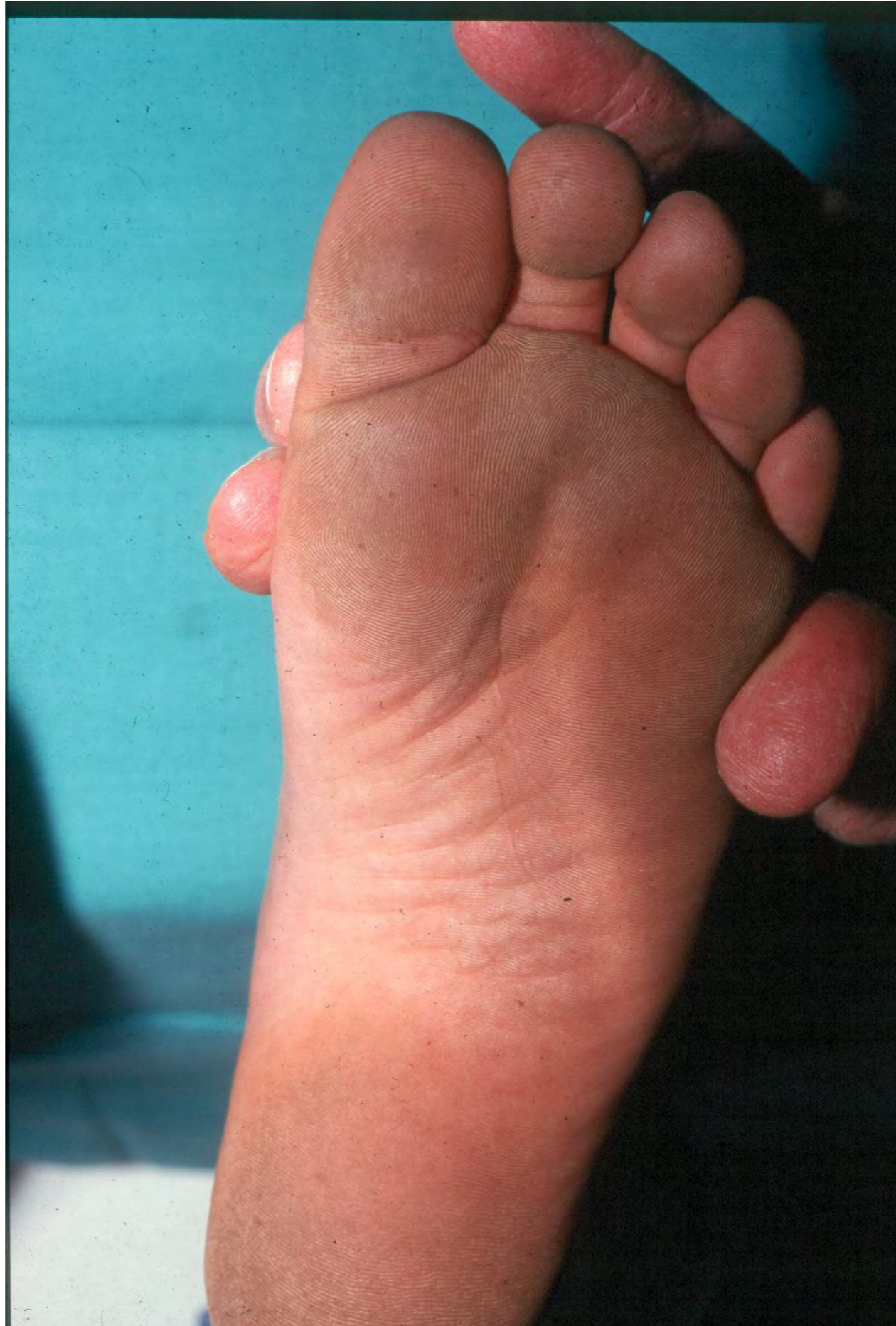
Sole of foot:

- Plantar warts
- Melanoma (unpigmented)
- Foreign body entrance



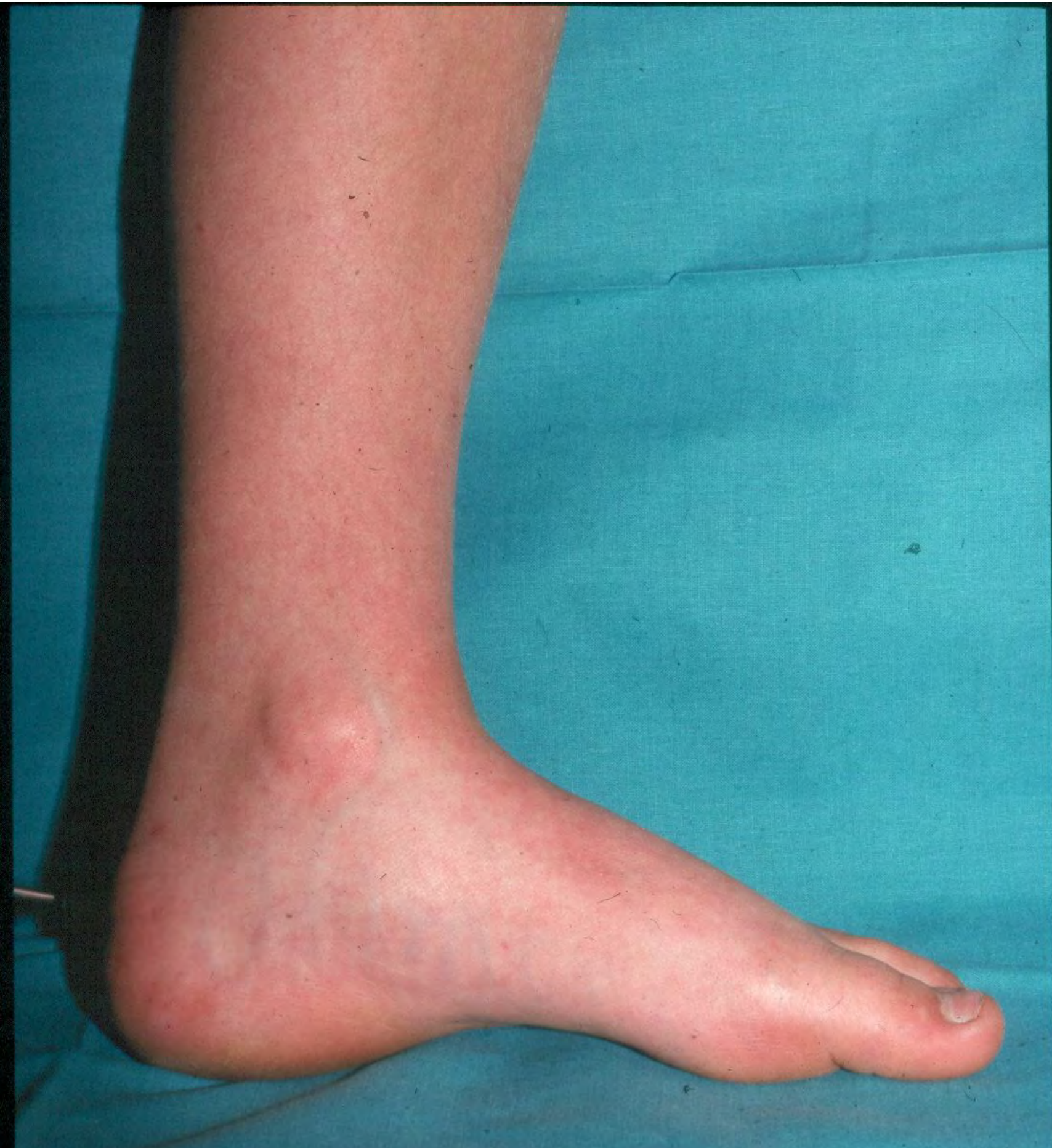Morton's interdigital neuroma



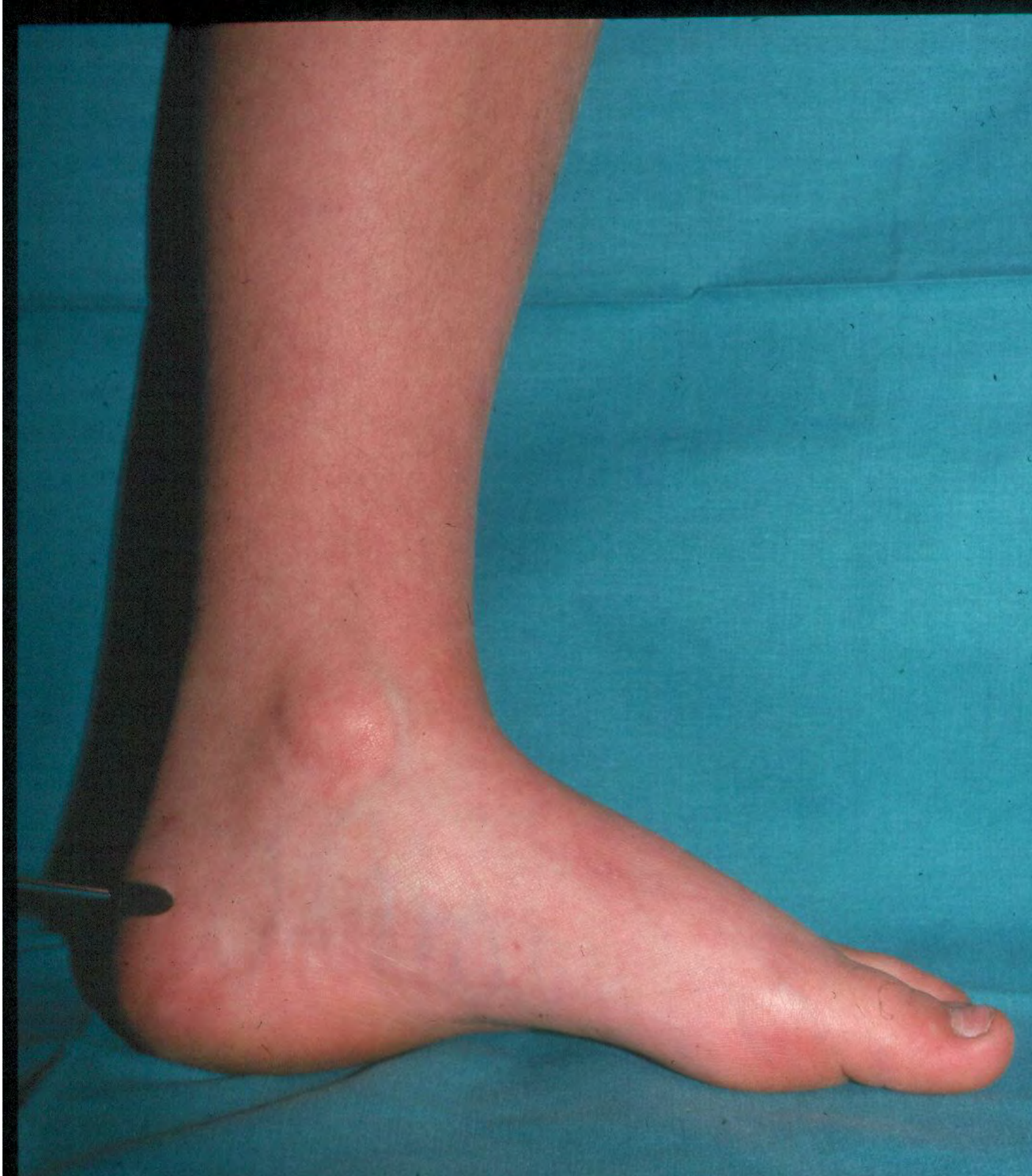

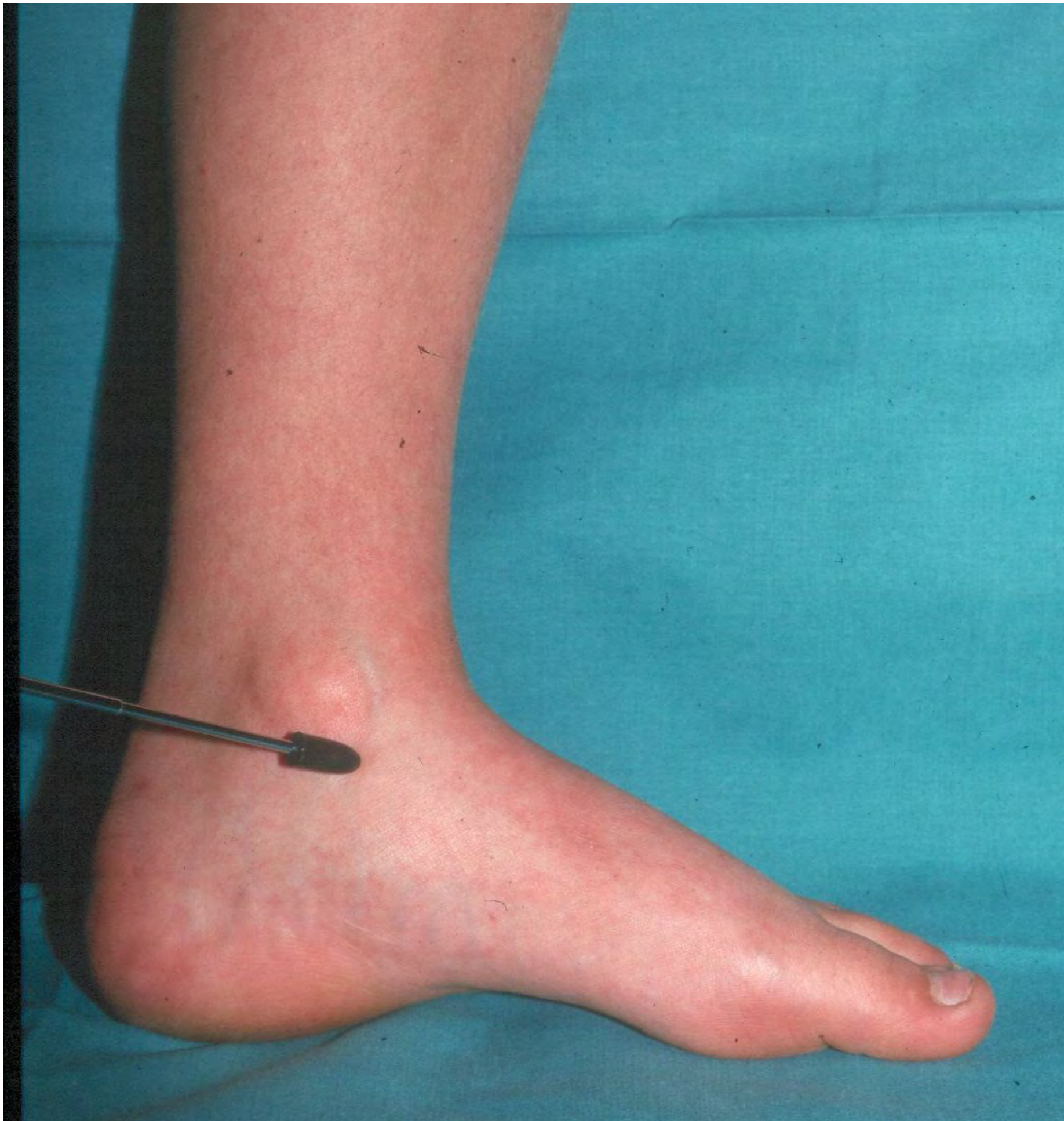Local tenderness

Patient must point
out where pain is

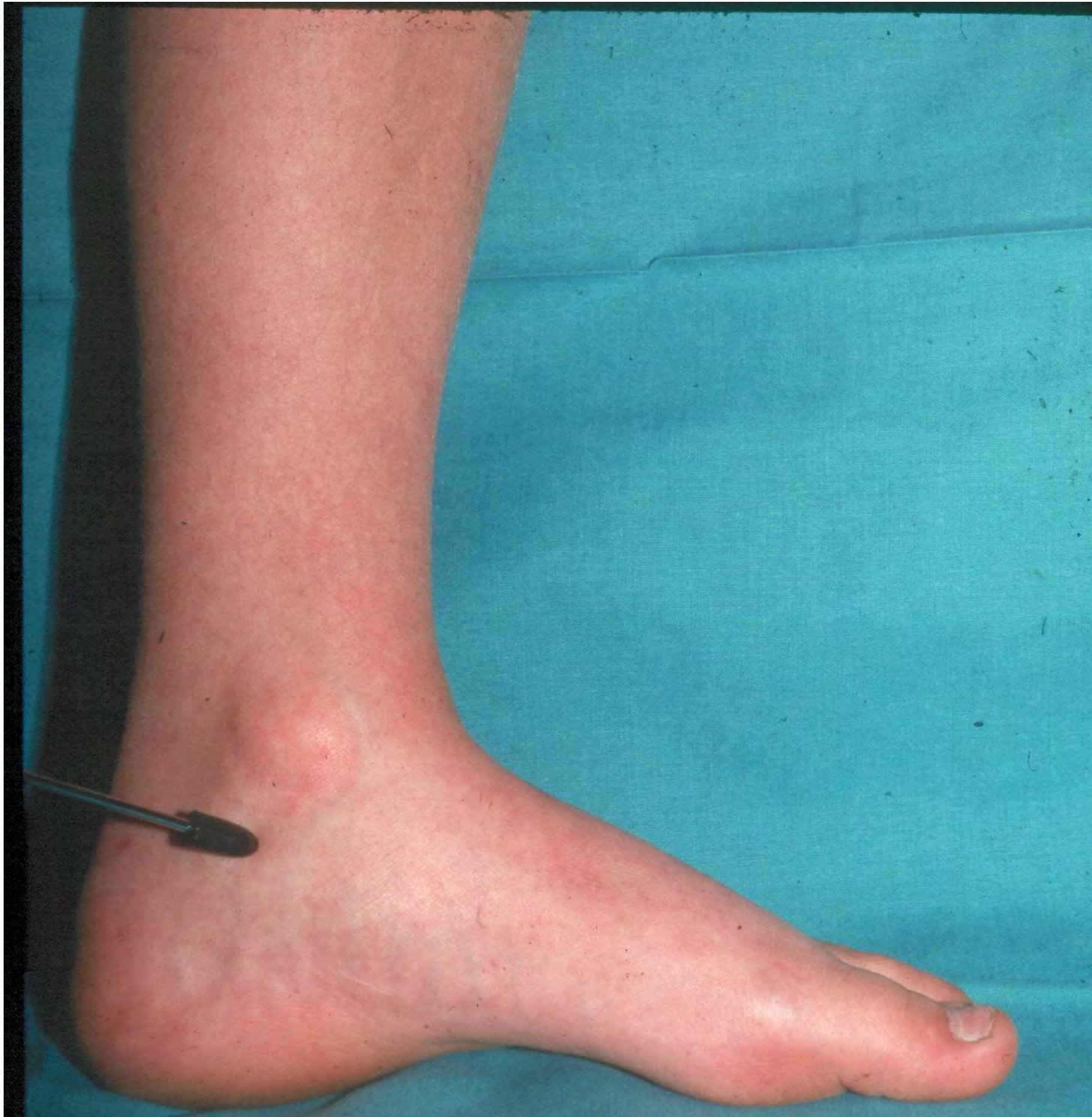

Bursa

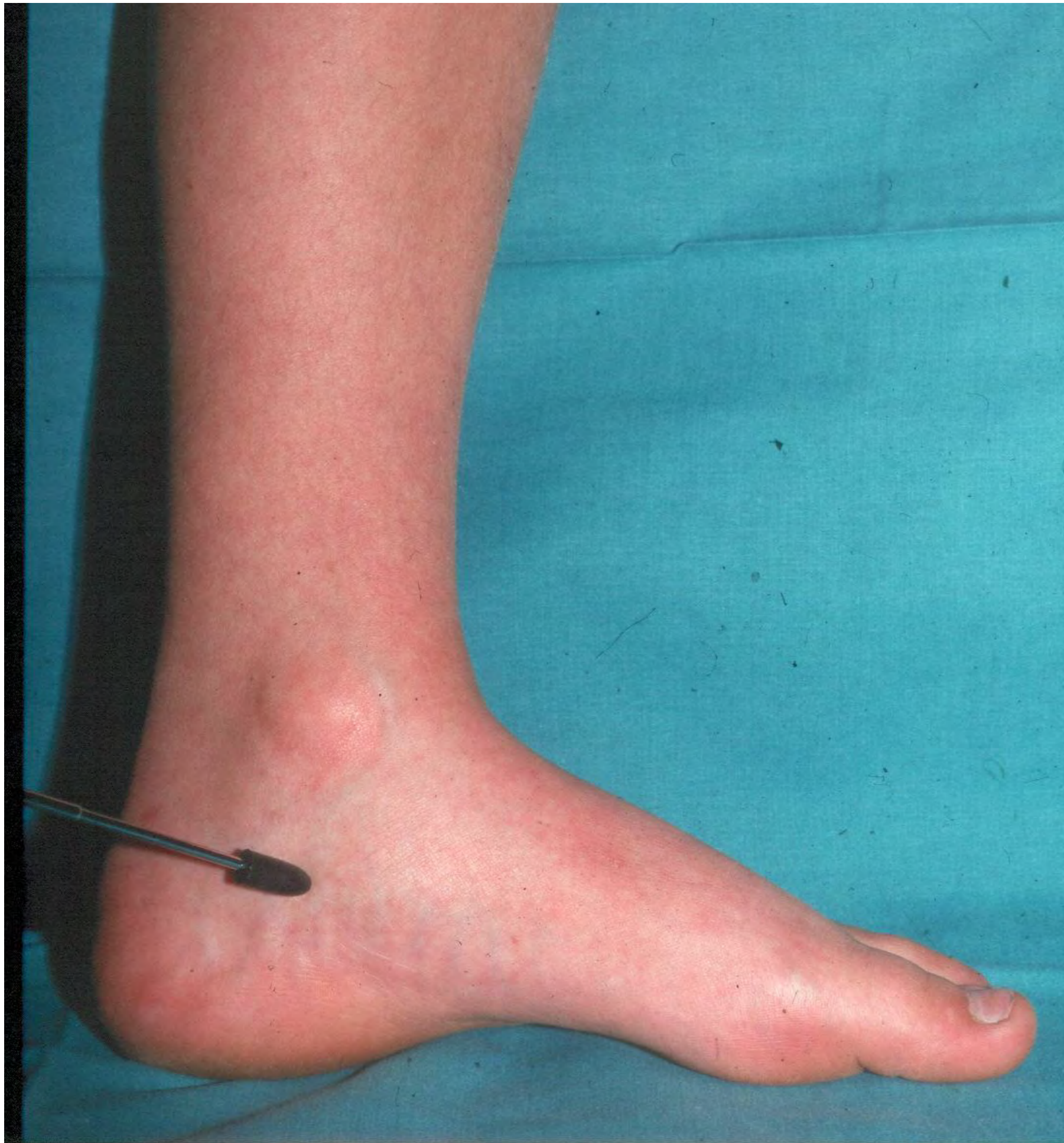



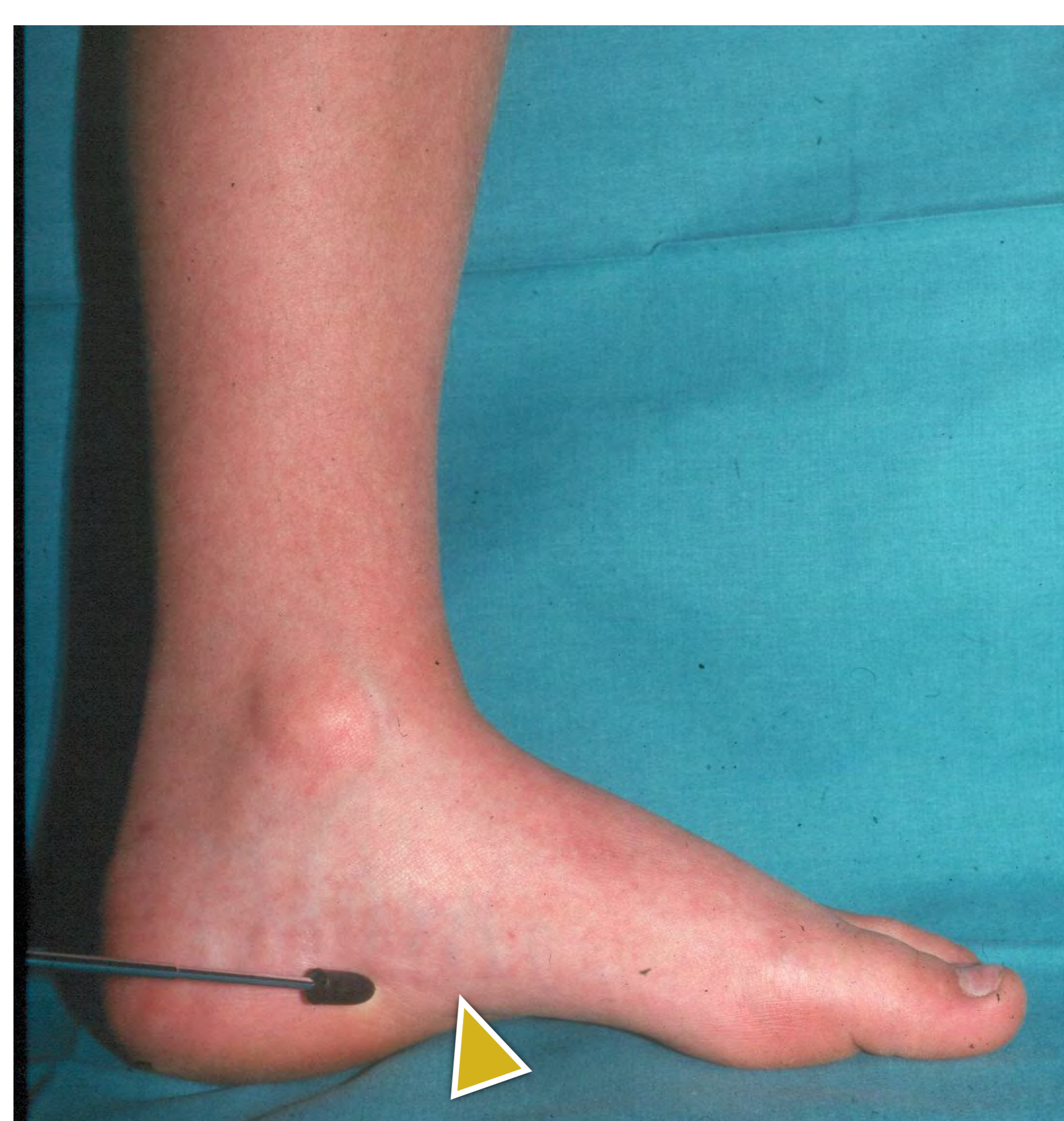
Medial Ligament



**Tibialis
posterior
tendon**

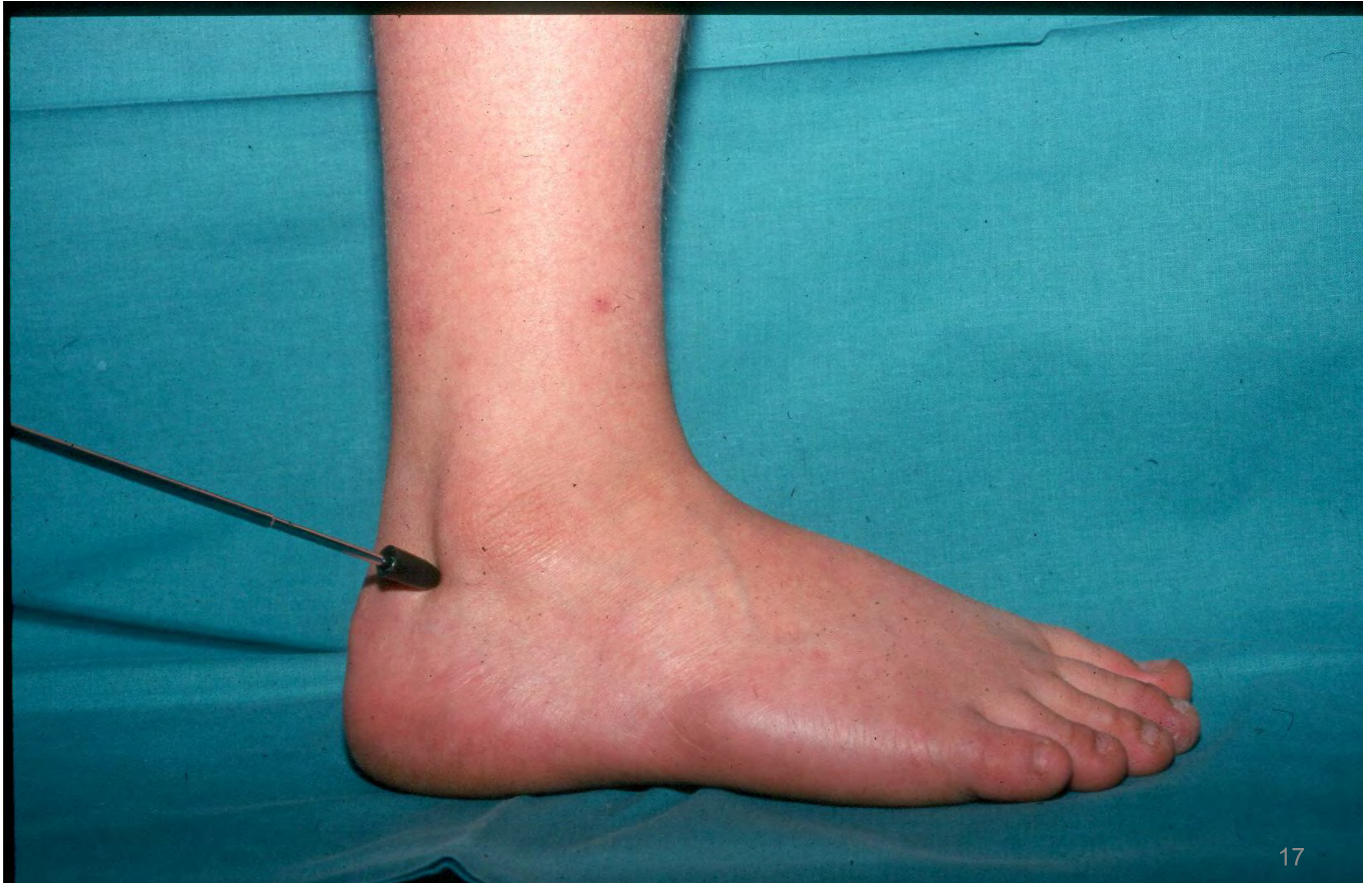

Neurovascular structures



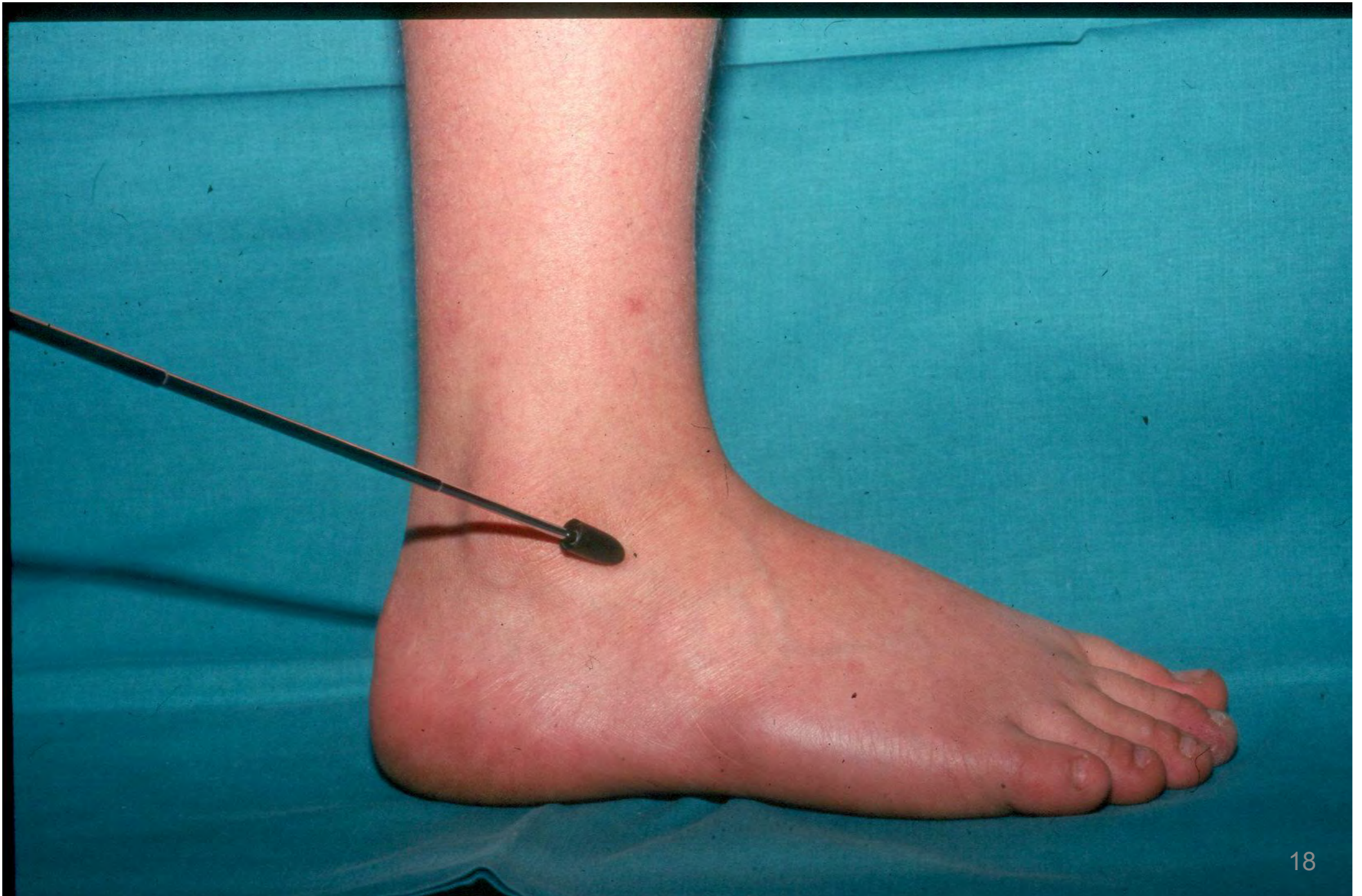**Plantar fasciitis
tenderness**

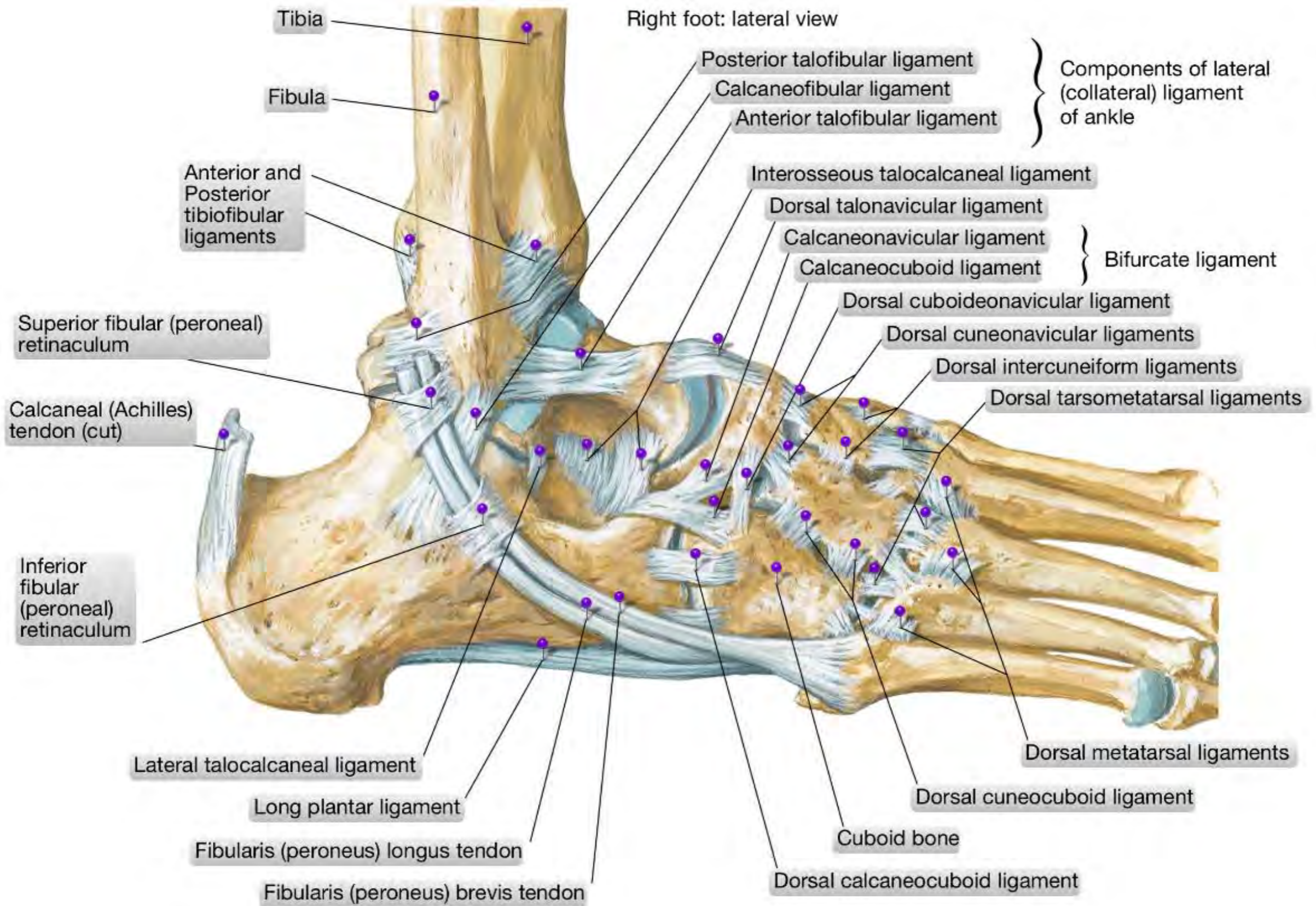
Peroneal tendons



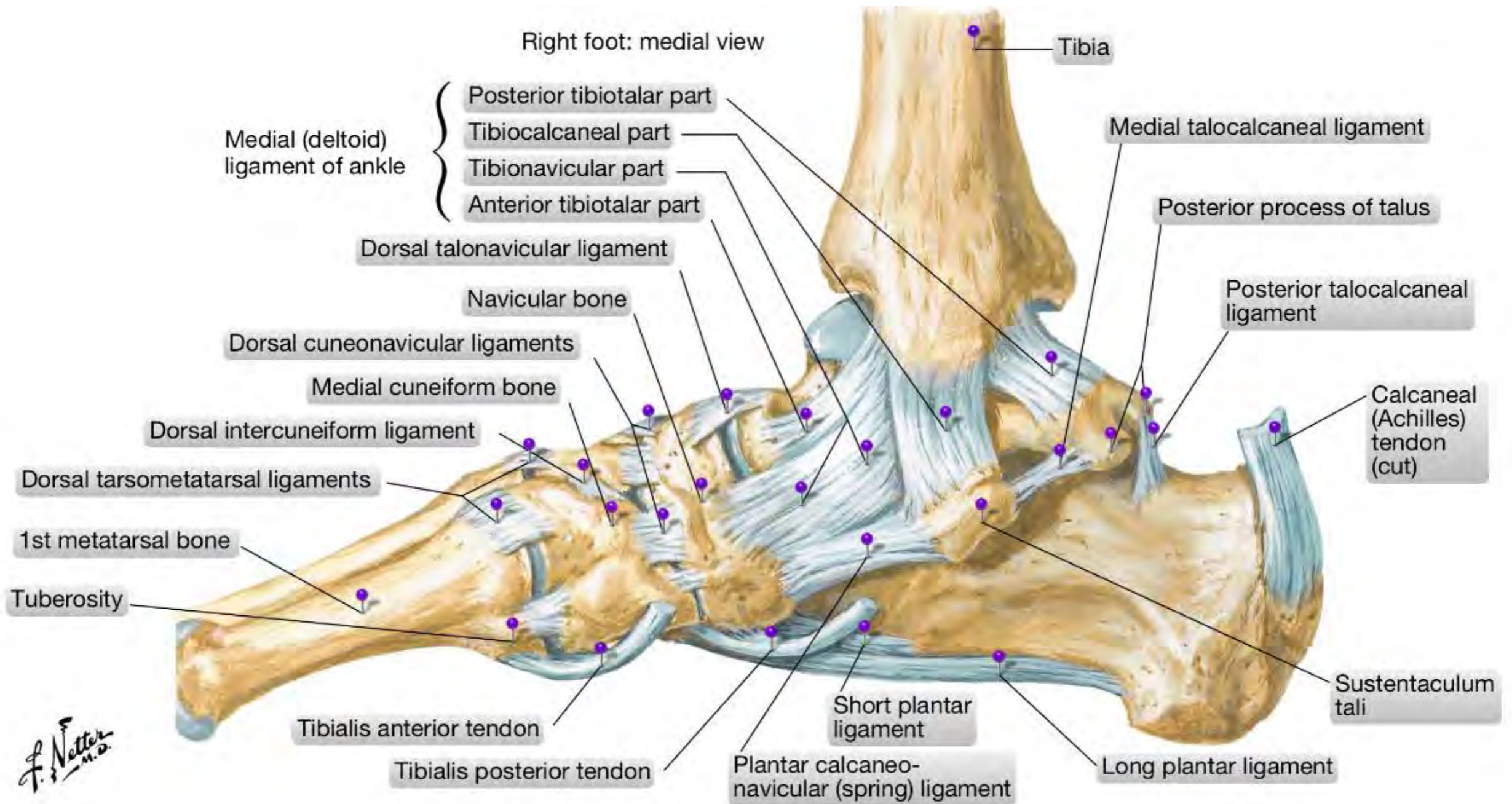
Sprained ankle

Lateral ligament of ankle, anterior part



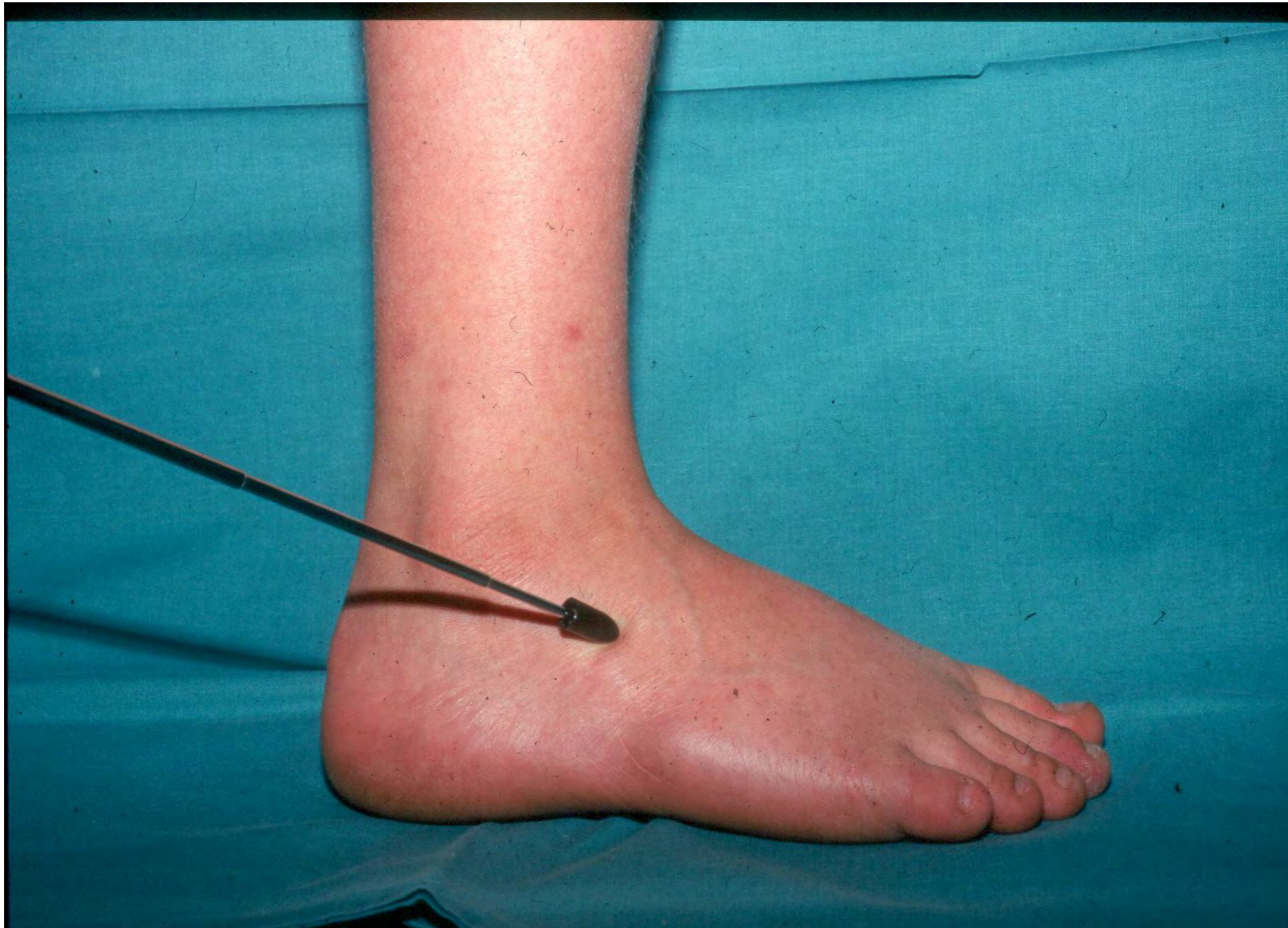

Right foot: medial view

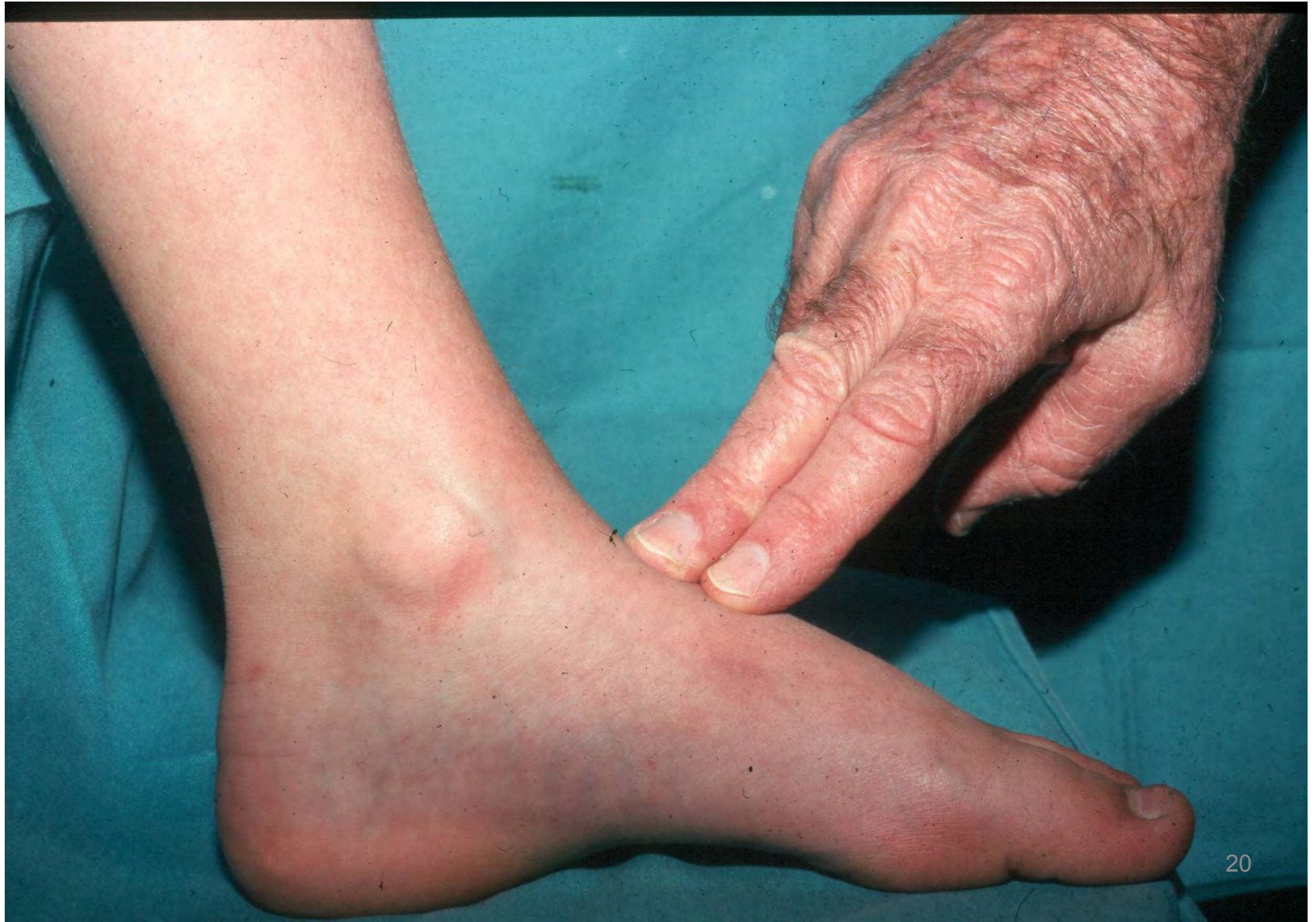

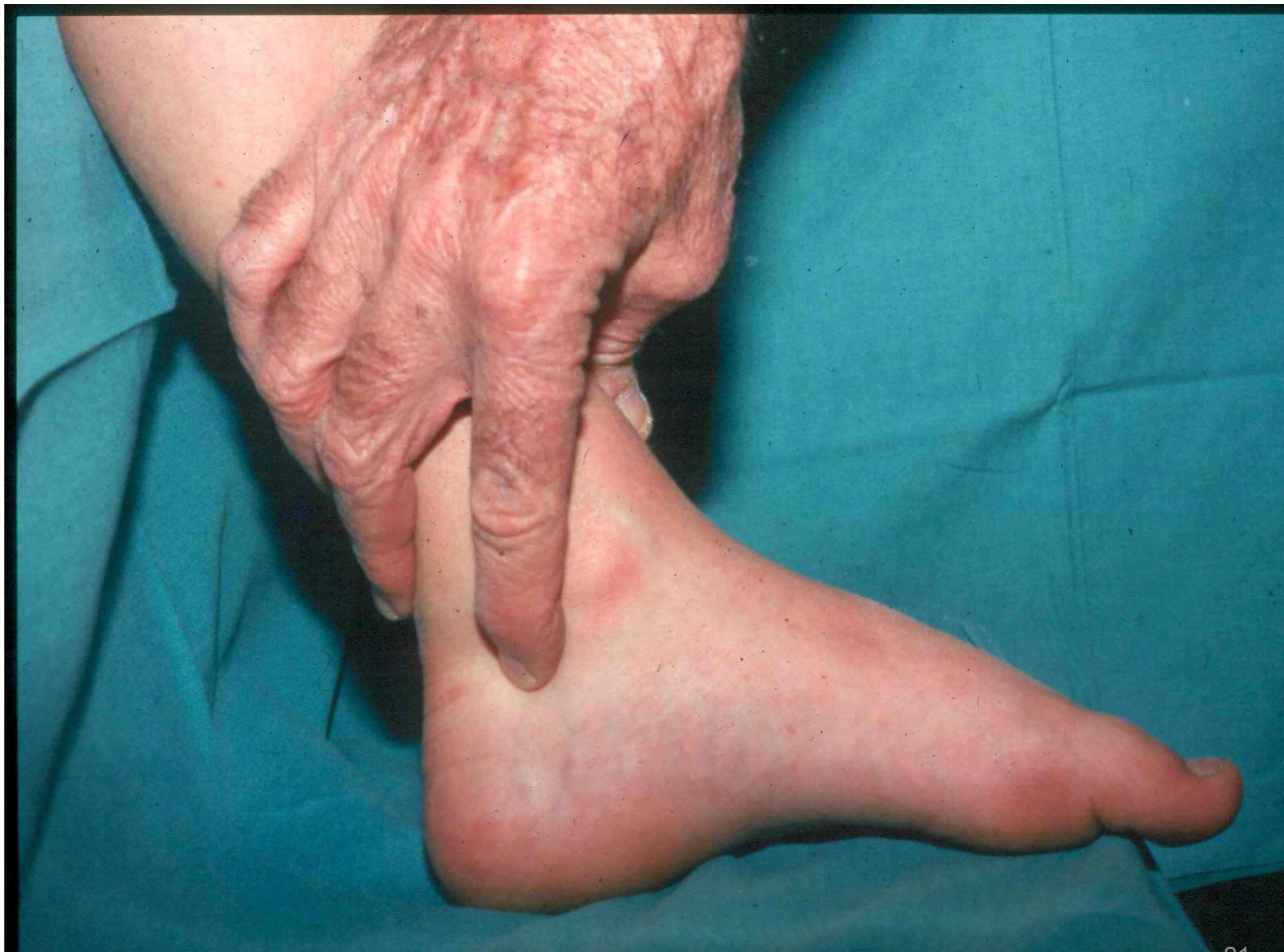F. Netter M.D.

Talo-calcaneofibular ligament



Feel for pulse! Vasculature NB

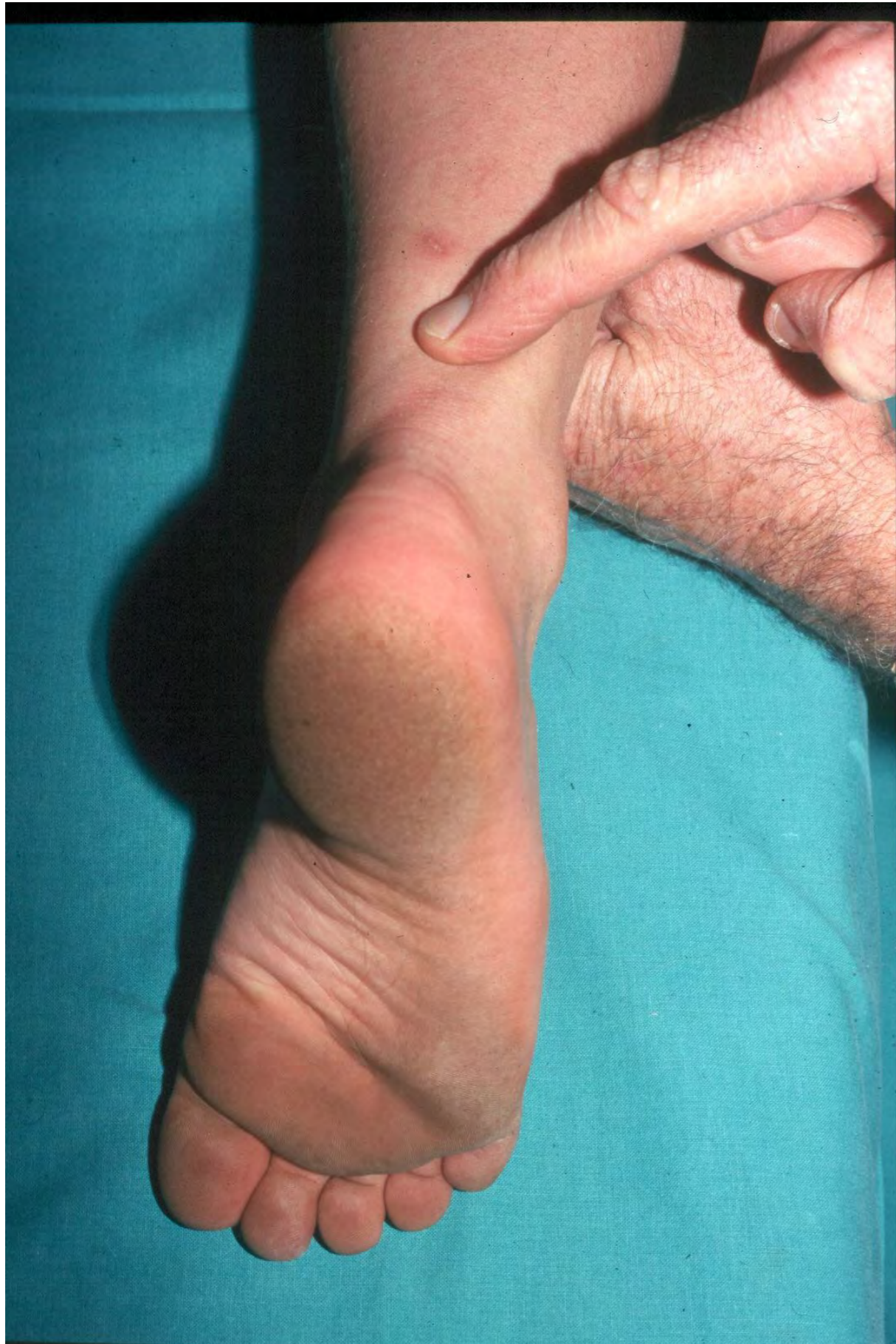




SENSATION

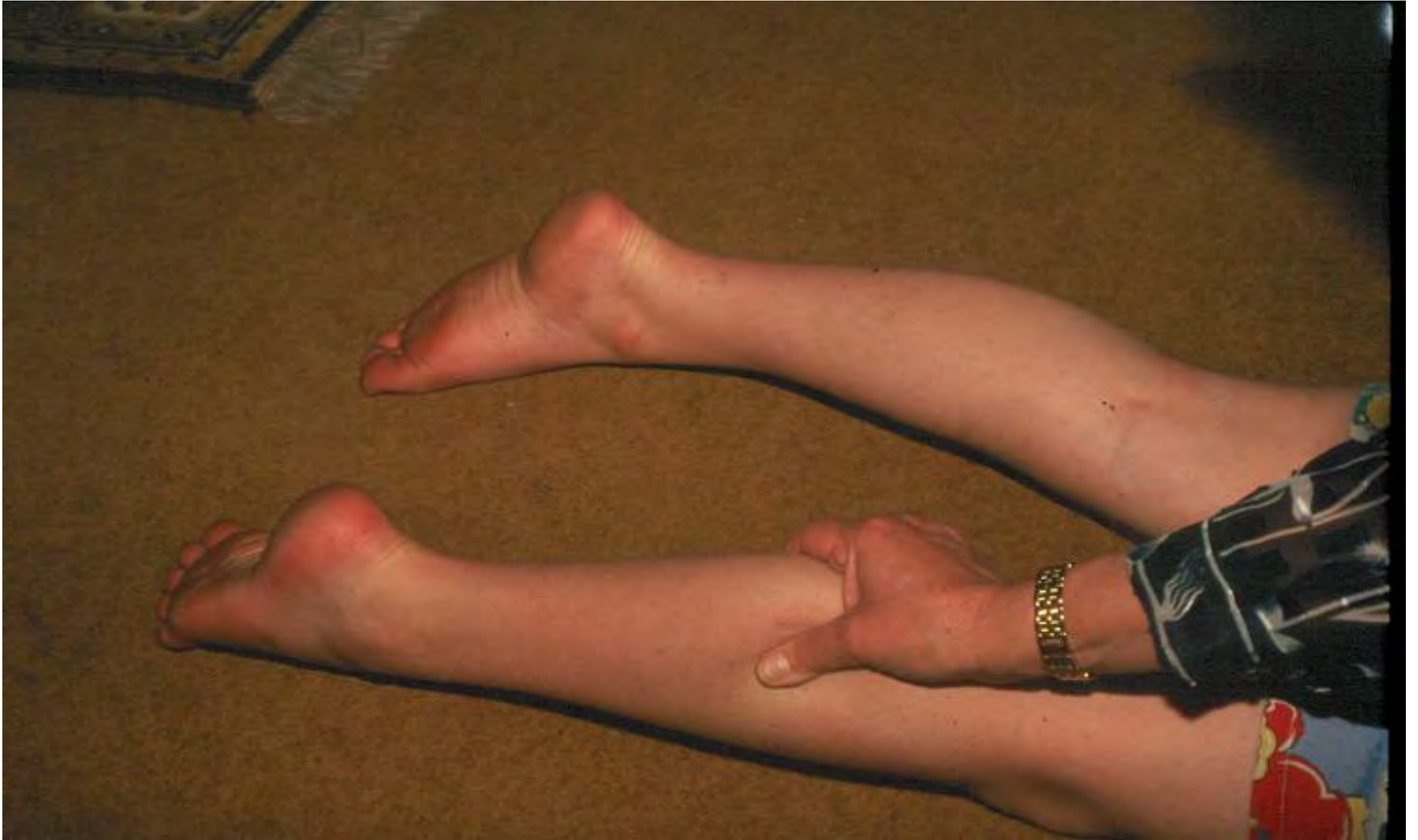Leg and foot

Diabetes



Achilles tendon rupture

Thompson's test



MOVEMENTS