HEAD INJURY

Dept Neurosurgery

- INTRODUCTION
- PATHOPHYSIOLOGY
- CLINICAL CLASSIFICATION
- MANAGEMENT
  - INVESTIGATIONS
  - TREATMENT

INTRODUCTION

Most head injuries are due to an impact between the head and another object.

Depending on the characteristics of the object (e.g. size, shape and hardness/softness) various resultant injuries appear.

It is not always necessary for the head to come into contact with an object for there to be a head injury - even a significant one for that matter. However, acceleration-deceleration without contact can occur (e.g. "shaken-baby syndrome") which can lead to neuronal damage and subdural haematomas.

DEFINITIONS

- CLOSED HEAD INJURY
  - Head injury <u>without</u> open scalp wounds
- OPEN HEAD INJURY
  - Head injury <u>with</u> open wounds
- PENETRATING HEAD INJURY
  - Head injury with interruption of the dura.
    - Eg. Knife, axe, Gunshot

PATHOPHYSIOLOGY

There is a primary and a secondary head injury or primary and secondary brain damage.

(A) PRIMARY HEAD INJURY:

A primary head injury is an injury that occurs at the moment of the impact or accident.

The following are results of a primary head injury:

- Concussion

A transient loss of consciousness for usually up to a few minutes, with subsequent recovery and no neurological deficit except amnesia.

- Brain Contusion

  Area of swelling & diffuse haemorrhages (e.g. a bruise). Coupe & contre-coupe contusions.

-Diffuse axonal injury

-Skull Fractures

  Open or closed skull fractures

(B) SECONDARY HEAD INJURY

A secondary head injury or secondary brain damage, is an injury due to something that develops after the impact or accident, and has adverse neuro-logical effects.

Clinically, a patient is intially well (even after a concussion), but later deteriorates.

Causes of Secondary Brain Damage (causes of deterioration)

IIntracranial Causes:

- Haematomas - extradural
  - subdural
  - intracerebral
- Brain oedema or swelling
- Meningitis/brain infections
- Obstructive hydrocephalus

II Extracranial Causes

- Hypoxia: leads to lactic acidosis and cerebral vasodilatation. This congestion leads to raised intracranial pressure.
- Hypercarbia: This also leads to cerebral vasodilatation and raised intracranial pressure.
- Hypotension: this leads to cerebral ischaemia.

Note: CPP = MAP - ICP

CPP = Cerebral perfusion pressure
MAP = Mean arterial pressure
ICP = Intracranial pressure
∴ Avoid ↓MAP of ↑ICP

CLINICAL CLASSIFICATION OF HEAD INJURY

Glasgow Coma Scale:

E: Eye opening response (1-4)

M: Motor response (1-6) i.e. Best Motor Response

V: Verbal response (1-5)

E:	**1**	**=**	**No eye opening**
	2	**=**	**Opens eyes to pain**
	3	**=**	**Opens eyes to sound**
	4	**=**	**Spontaneous eye opening**

M: 1 = No motor response

2 = Extensor/decerebrate response (rigidity)

3 = Flexor/decorticate response (rigidity)

4 = Withdrawal response

5 = Purposeful response

6 = Obeys commands

V: 1 = No response

2 = Makes sounds only (to painful stimulation)

3 = Utters words only

4 = Says phrases, but confused

5 = Well orientated to time, place & person

GCS - used to monitor daily progress, and detect deterioration early.

GCS - also useful in classifying the severity of the head injury (and prognosticating)

e.g. Mild head injury: 13-15

Moderate head injury: 9-12

Severe head injury: 3-8

CT BRAIN

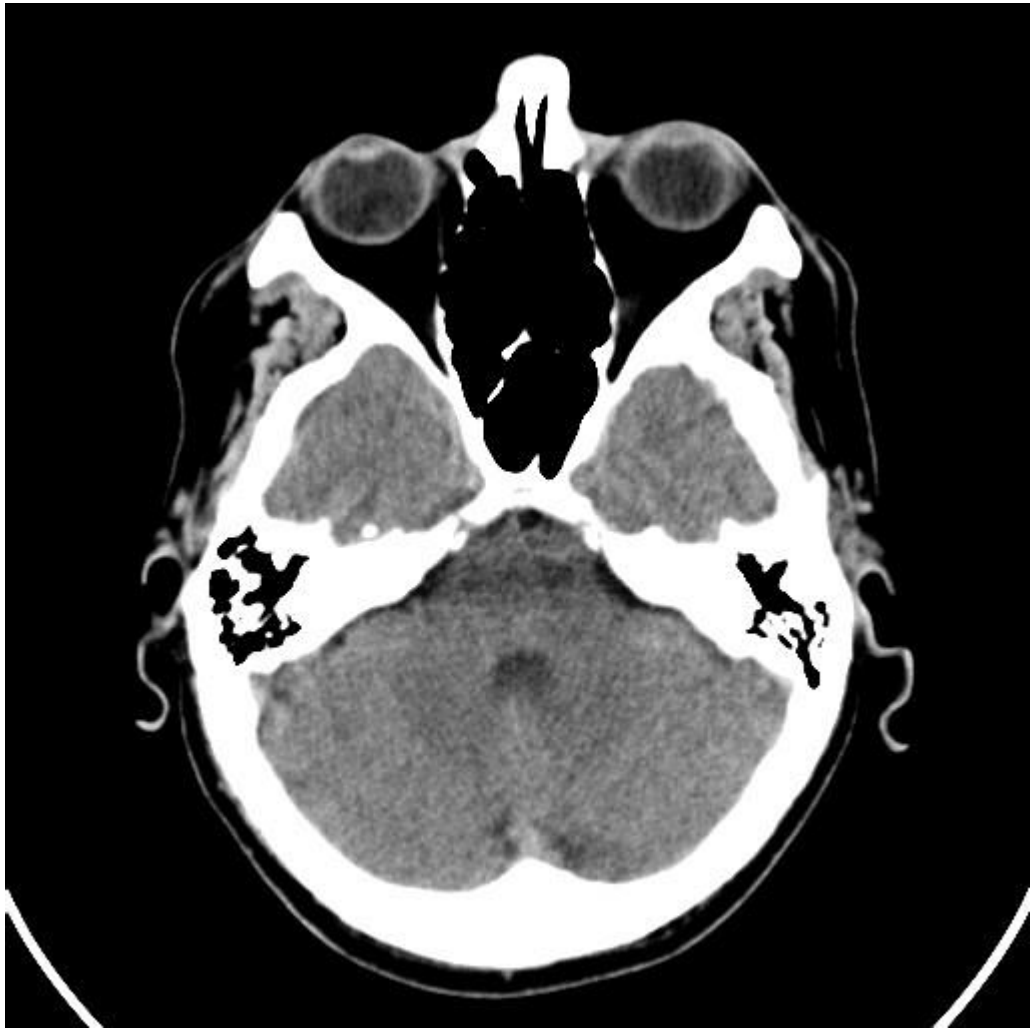

CT BRAIN

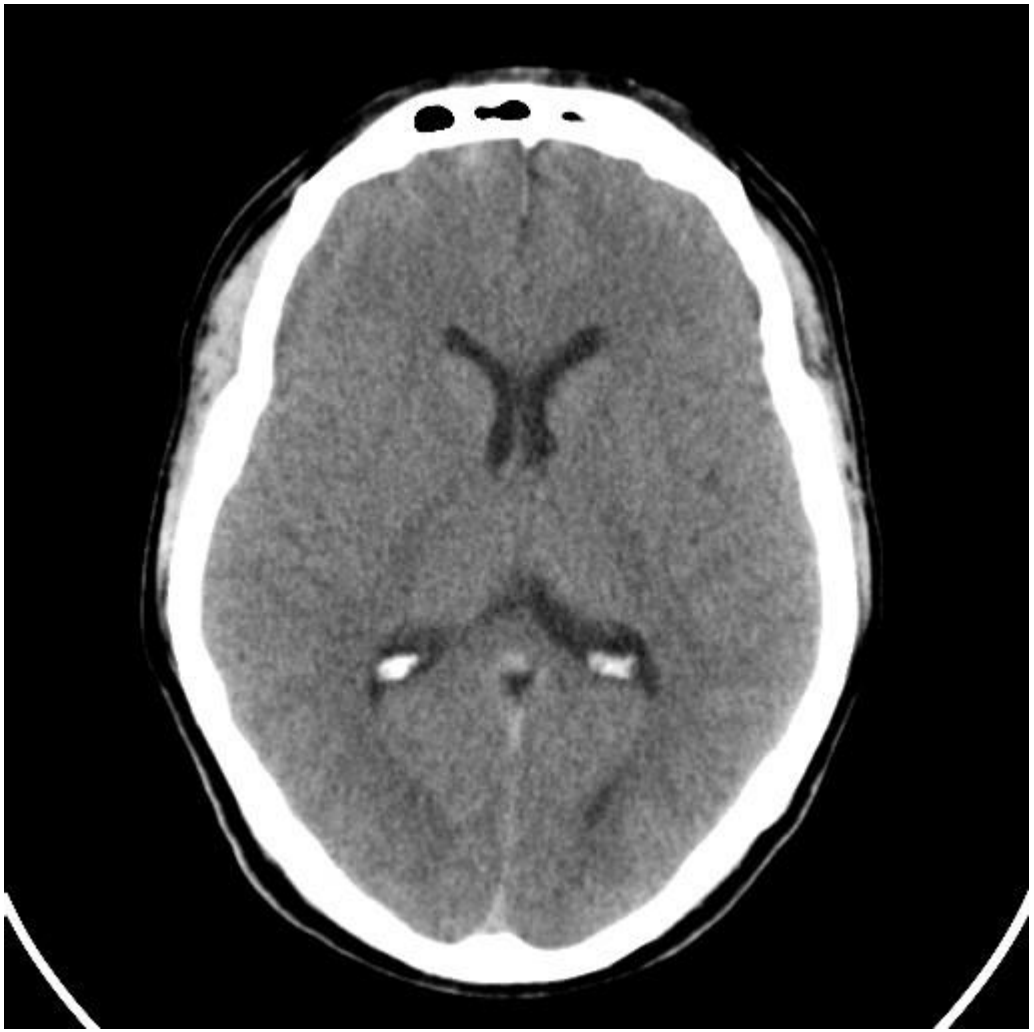

CT BRAIN

CT BRAIN

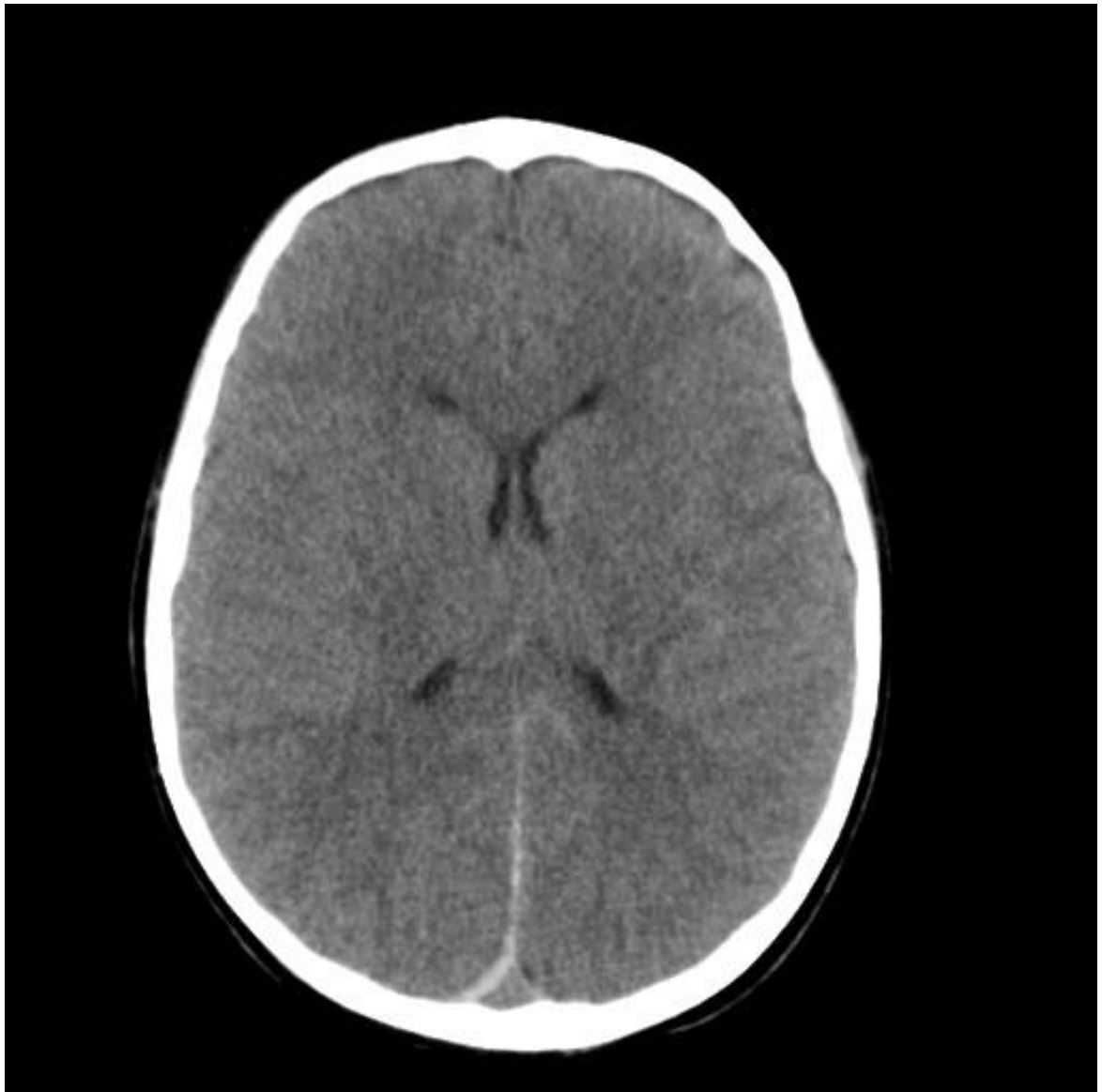

TBI-1

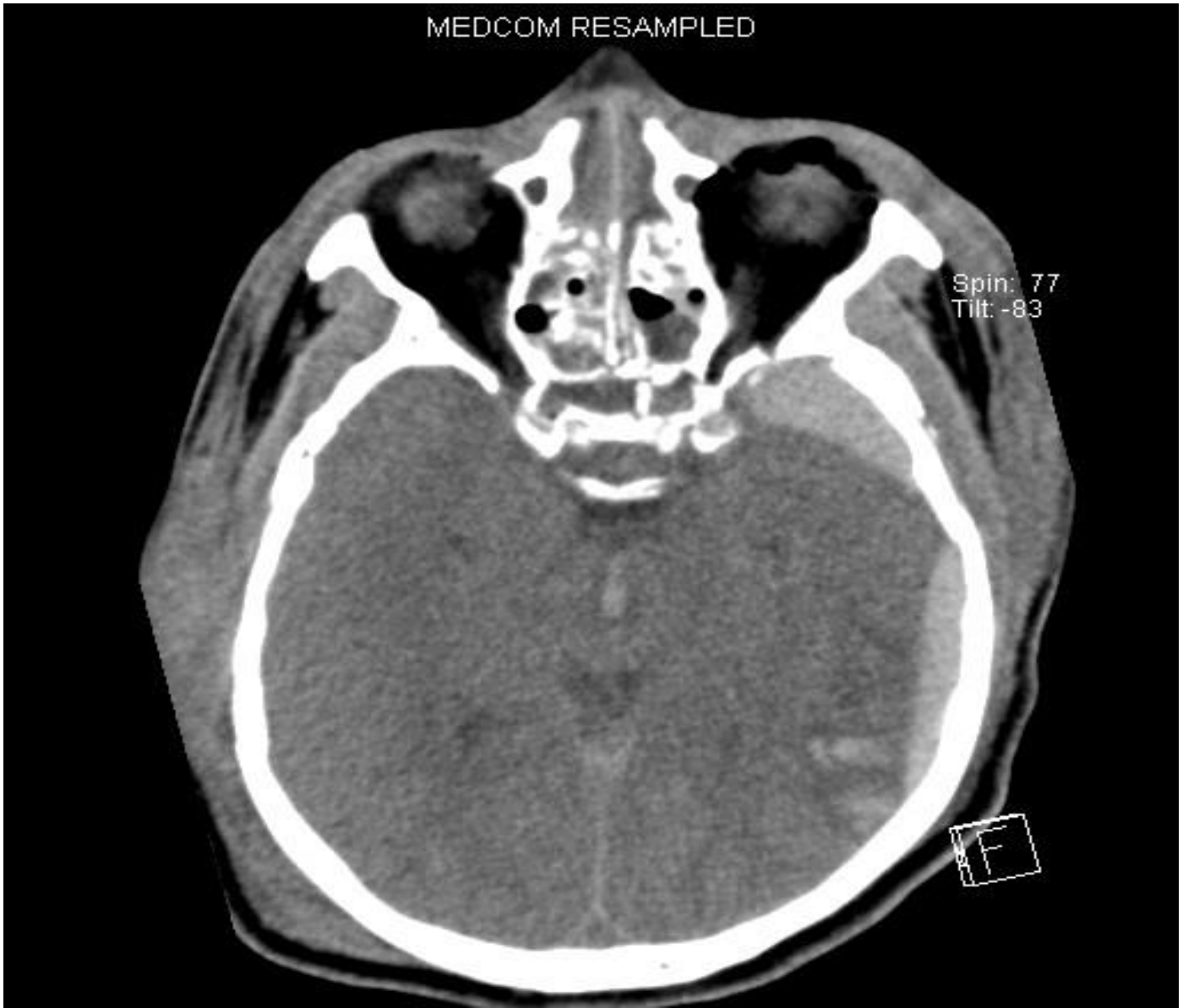

TBI-2

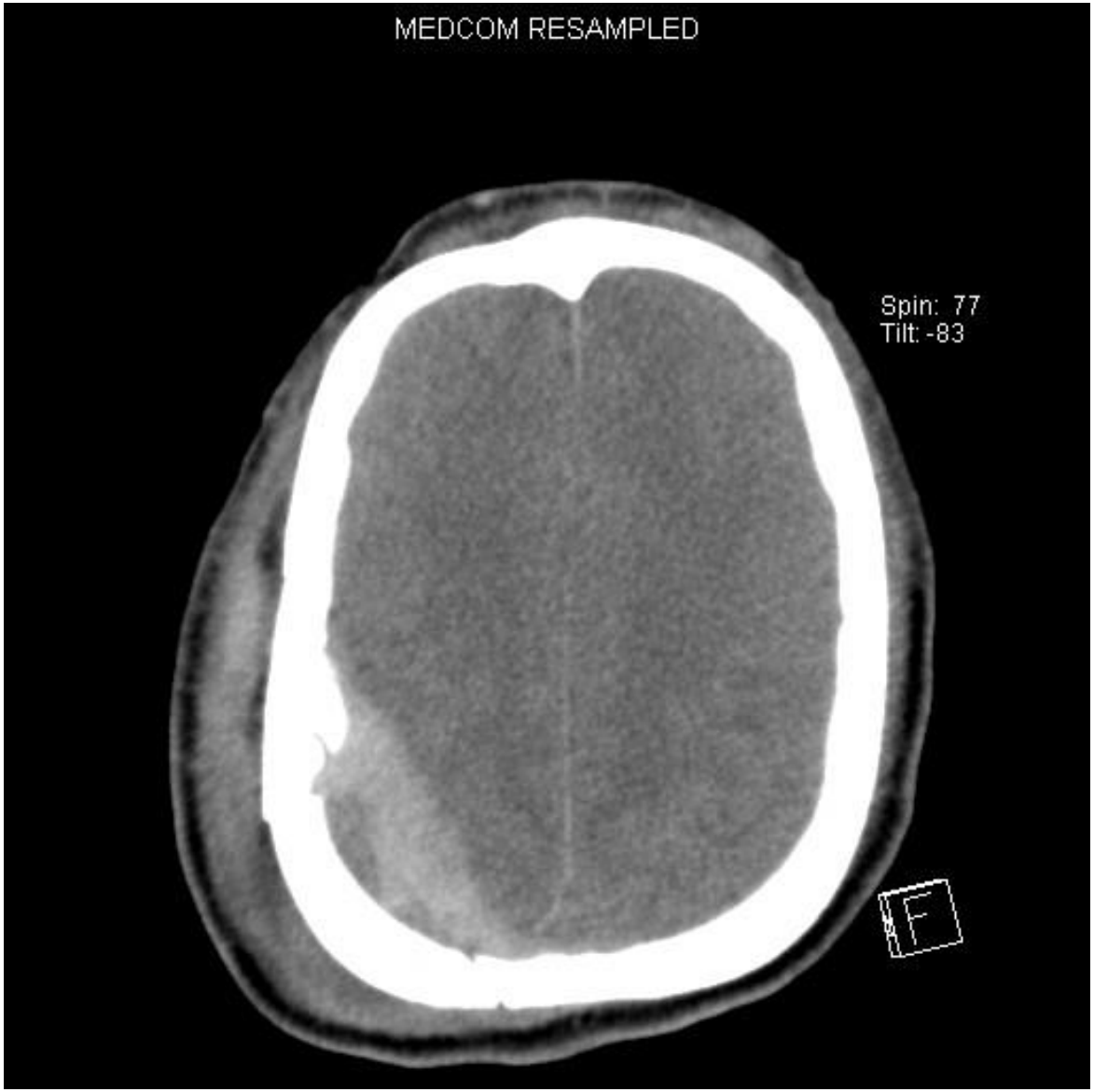

TBI-3

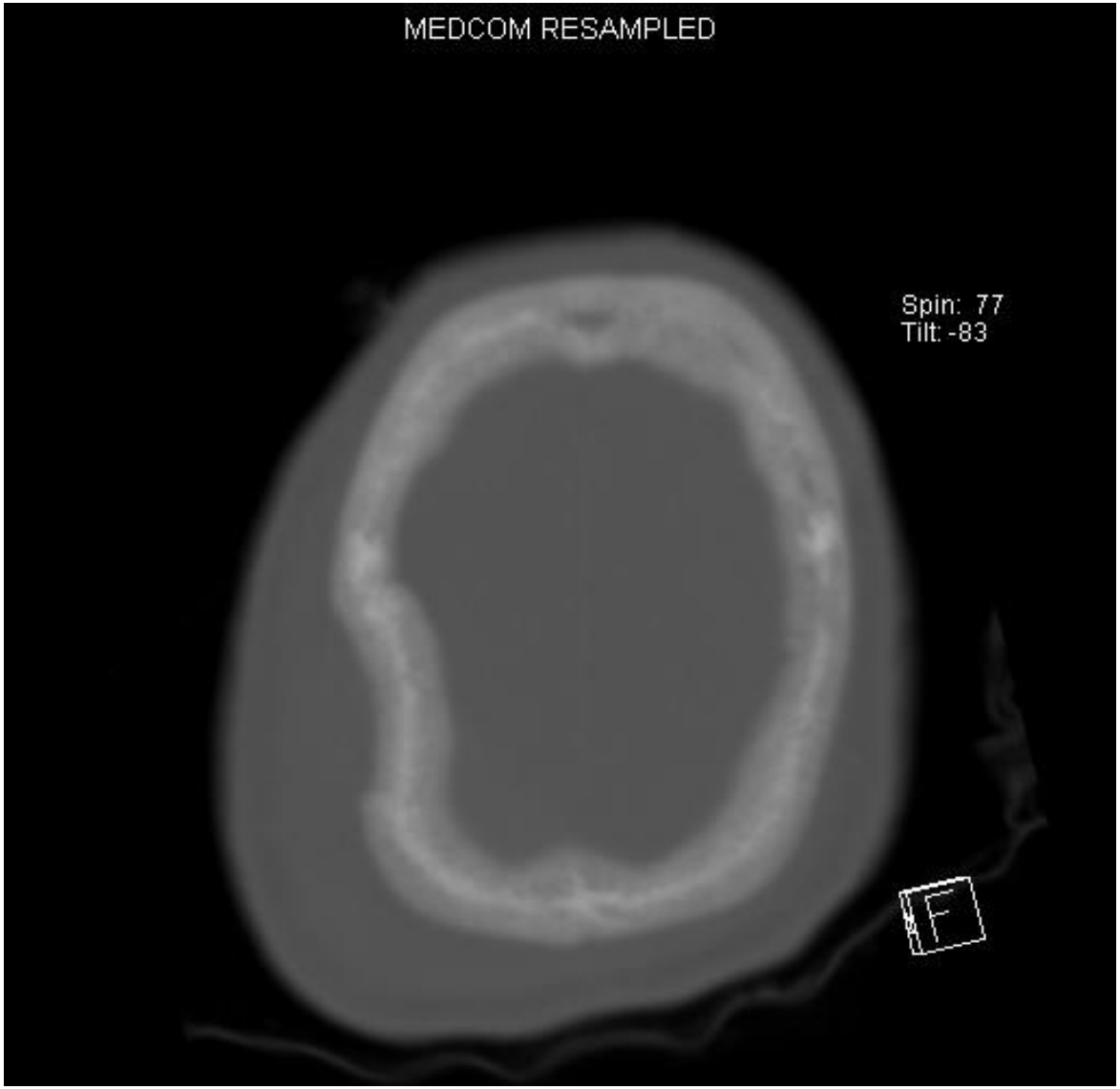

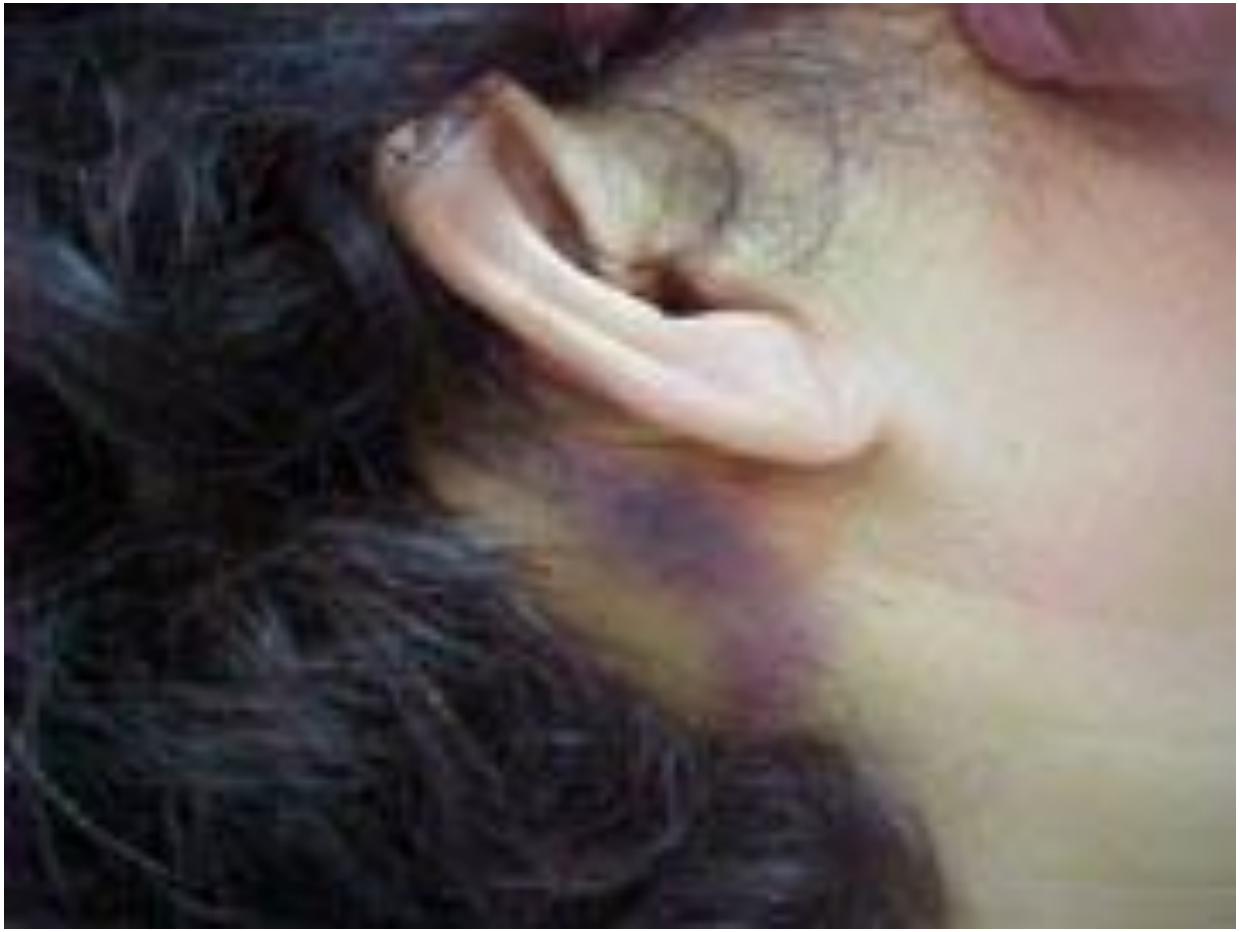

2. What sign is exhibited above?

   Watter teken word hierbo vertoon?

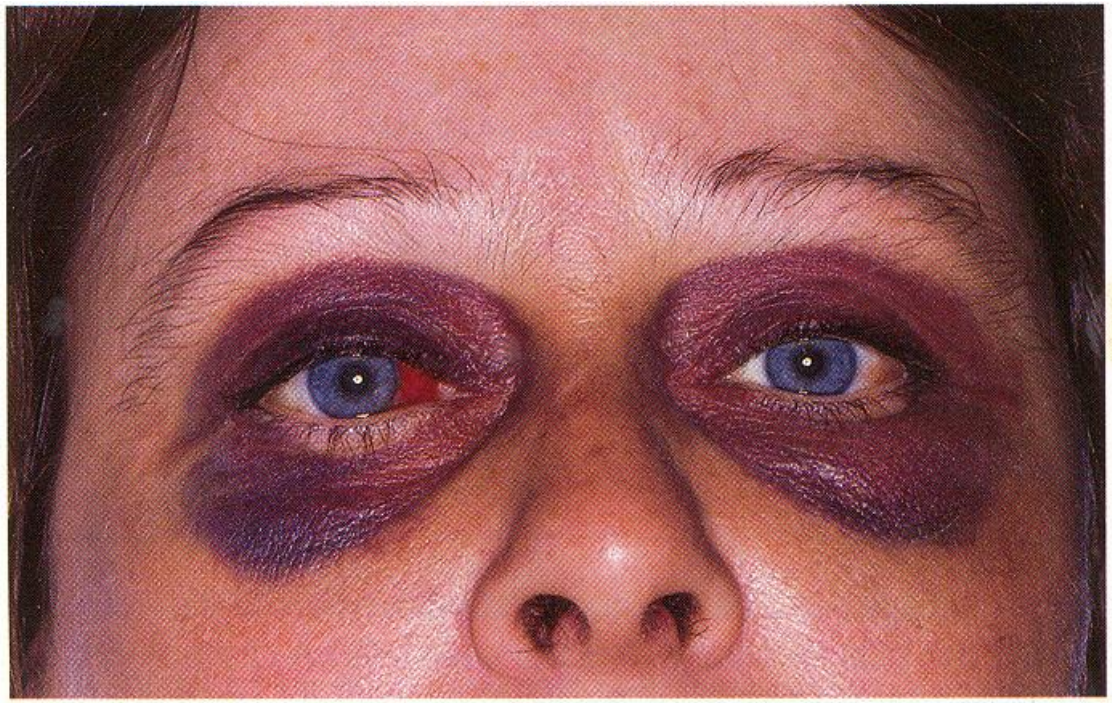

14. What clinical sign is exhibited above?

    Watter kliniese teken word hierbo vertoon?

BOSF-1

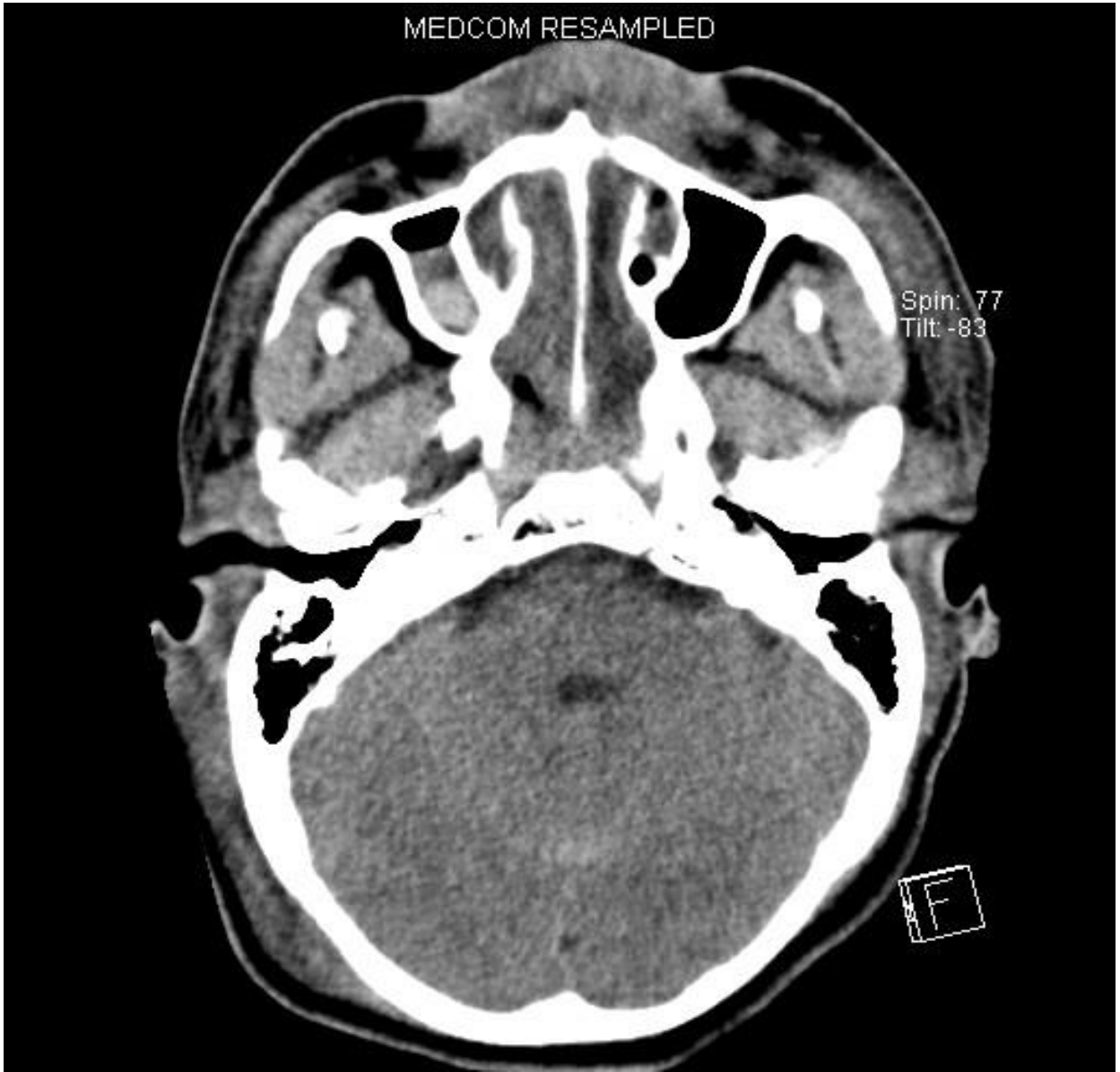

BOSF-2

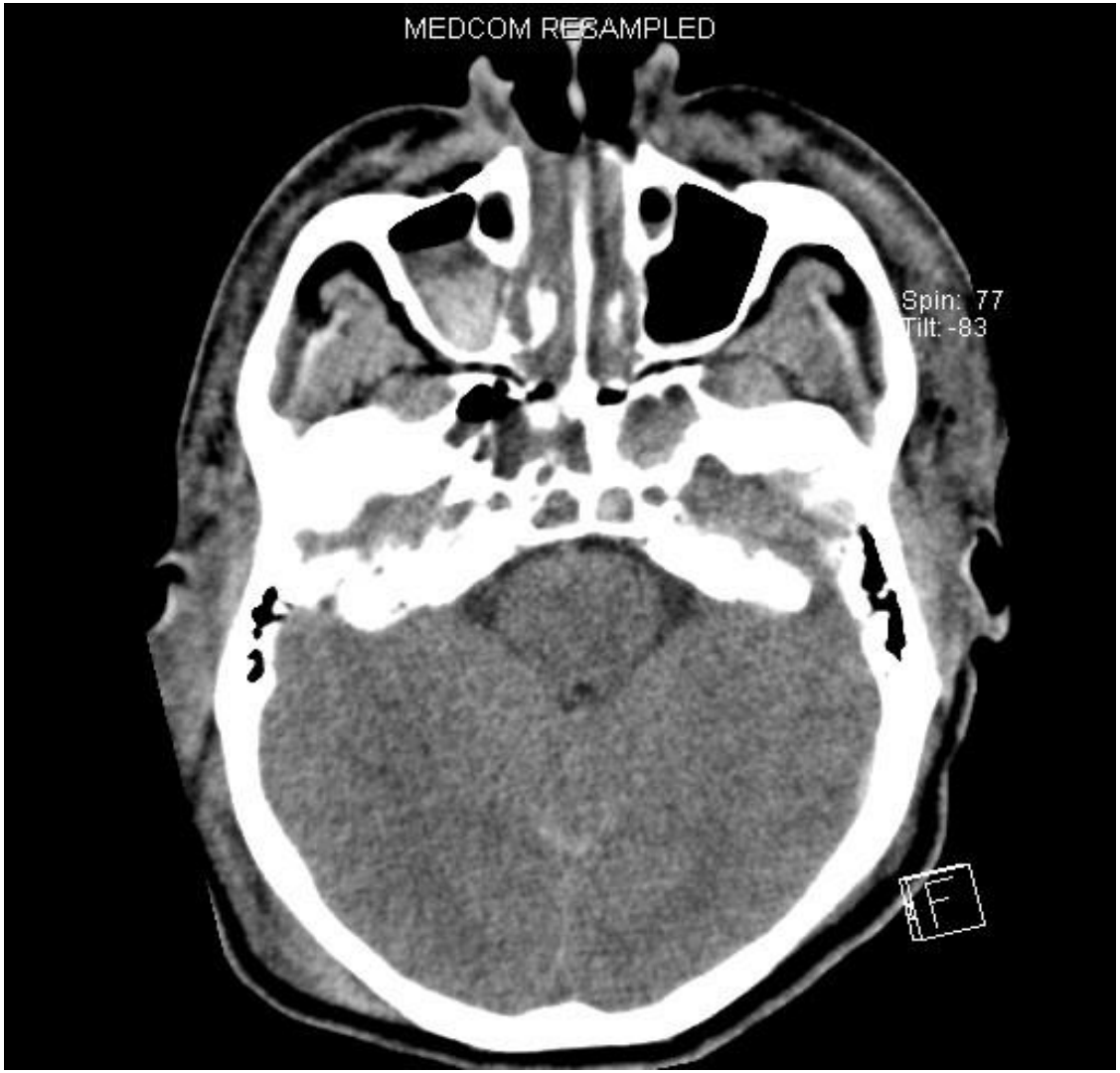

TBI-CNT

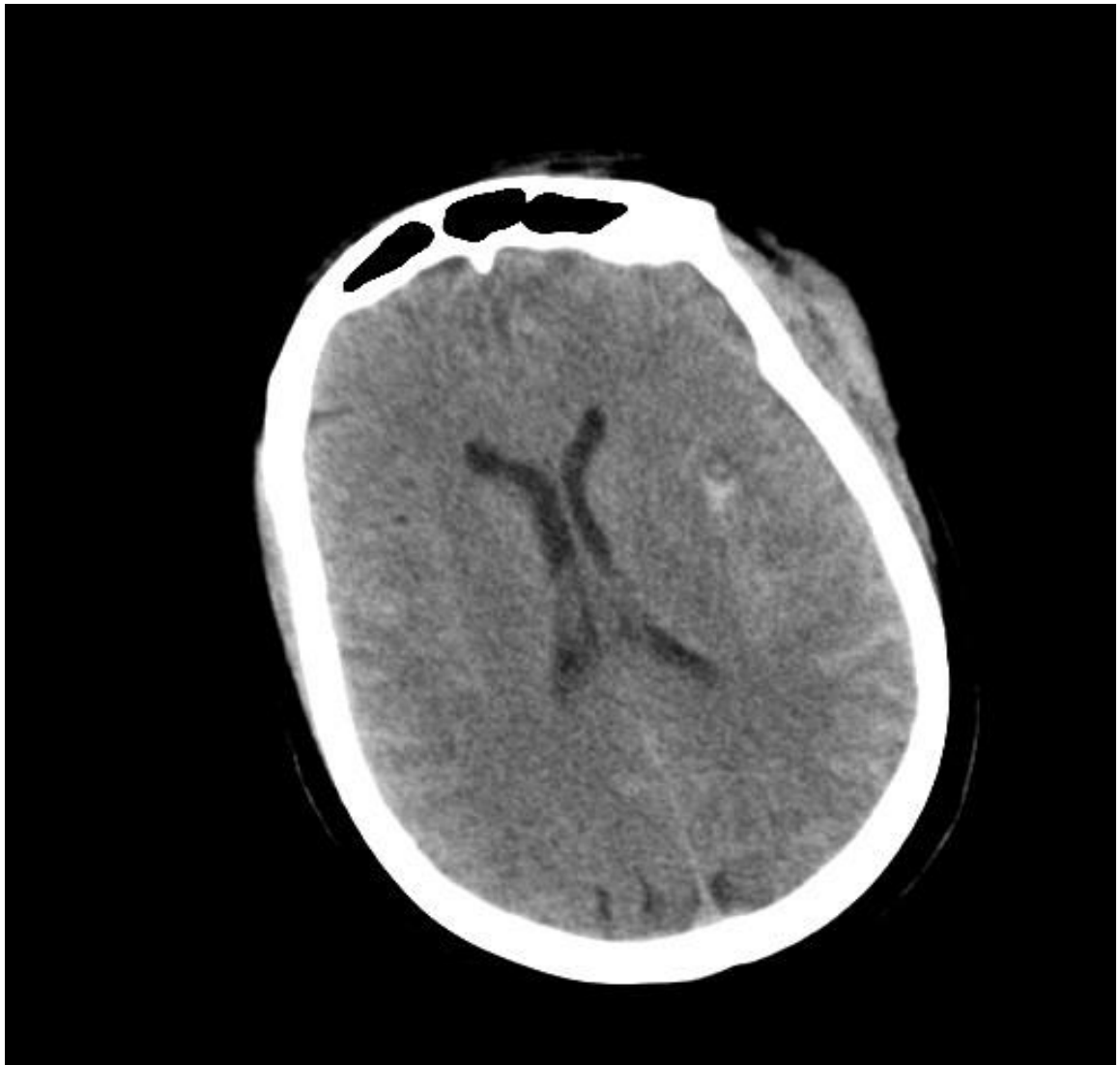

TBI-SAH

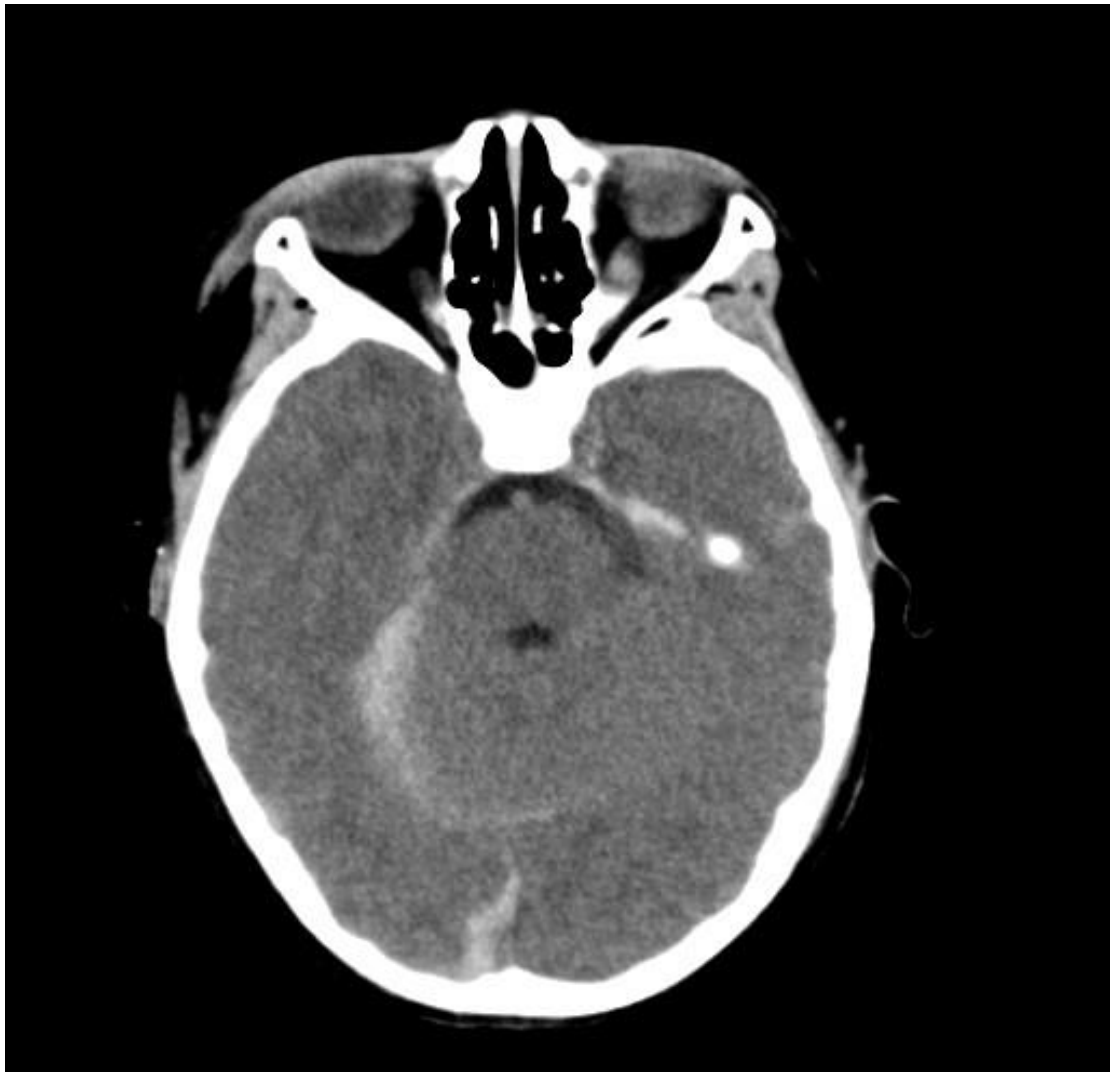

TBI-IVH

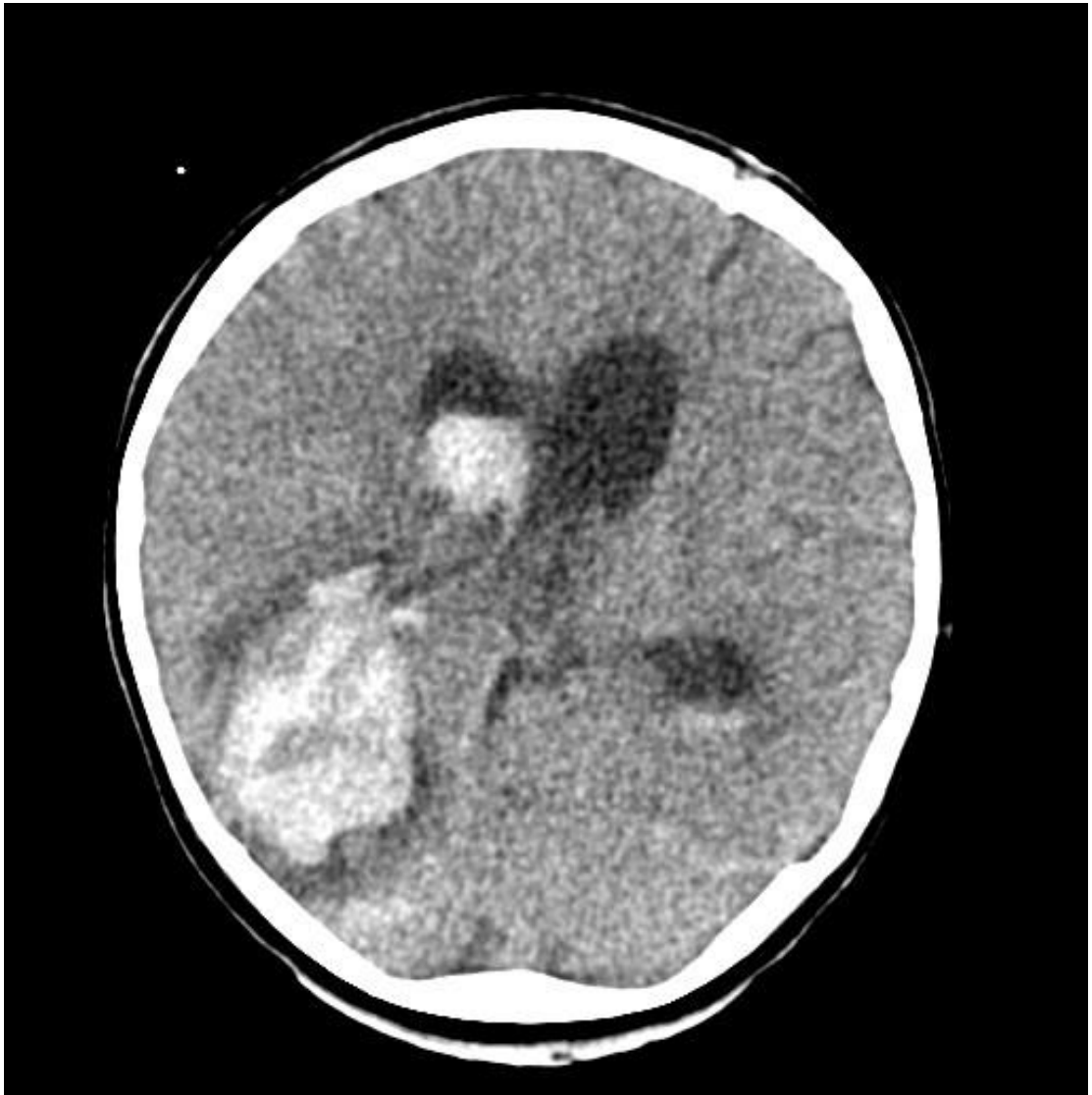

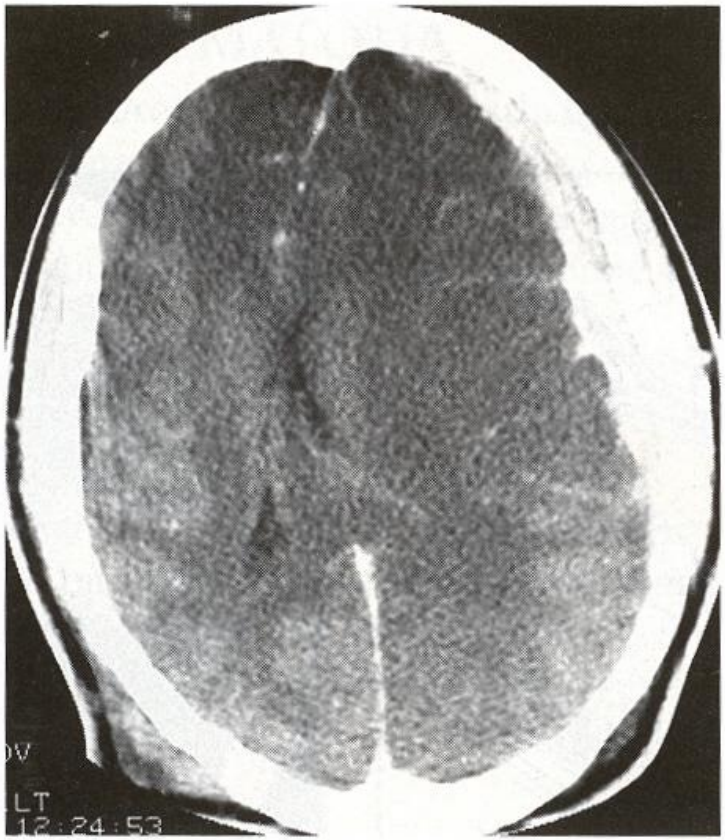

5. What intracranial bleed is represented on the CT scan?

Watter intrakraniale bloeding word op die RT skandering afgebeeld?

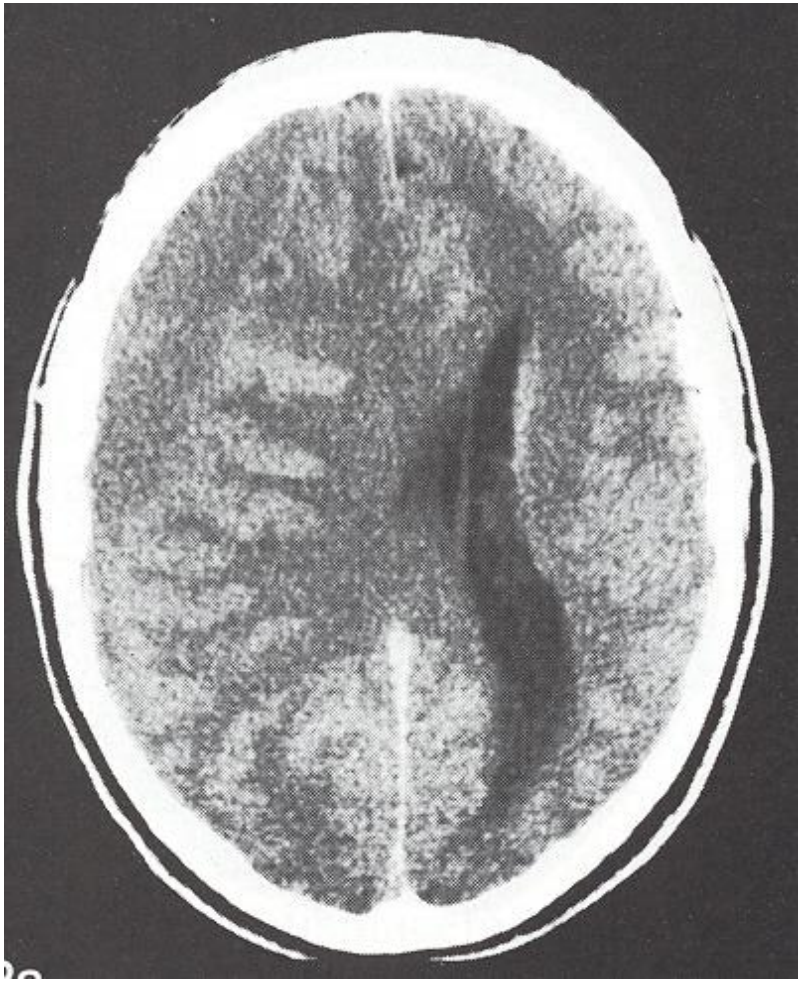

6. What intracranial bleed is represented on the CT scan?

Watter intrakraniale bloeding word op die RT skandering afgebeeld?

TBI-SDH

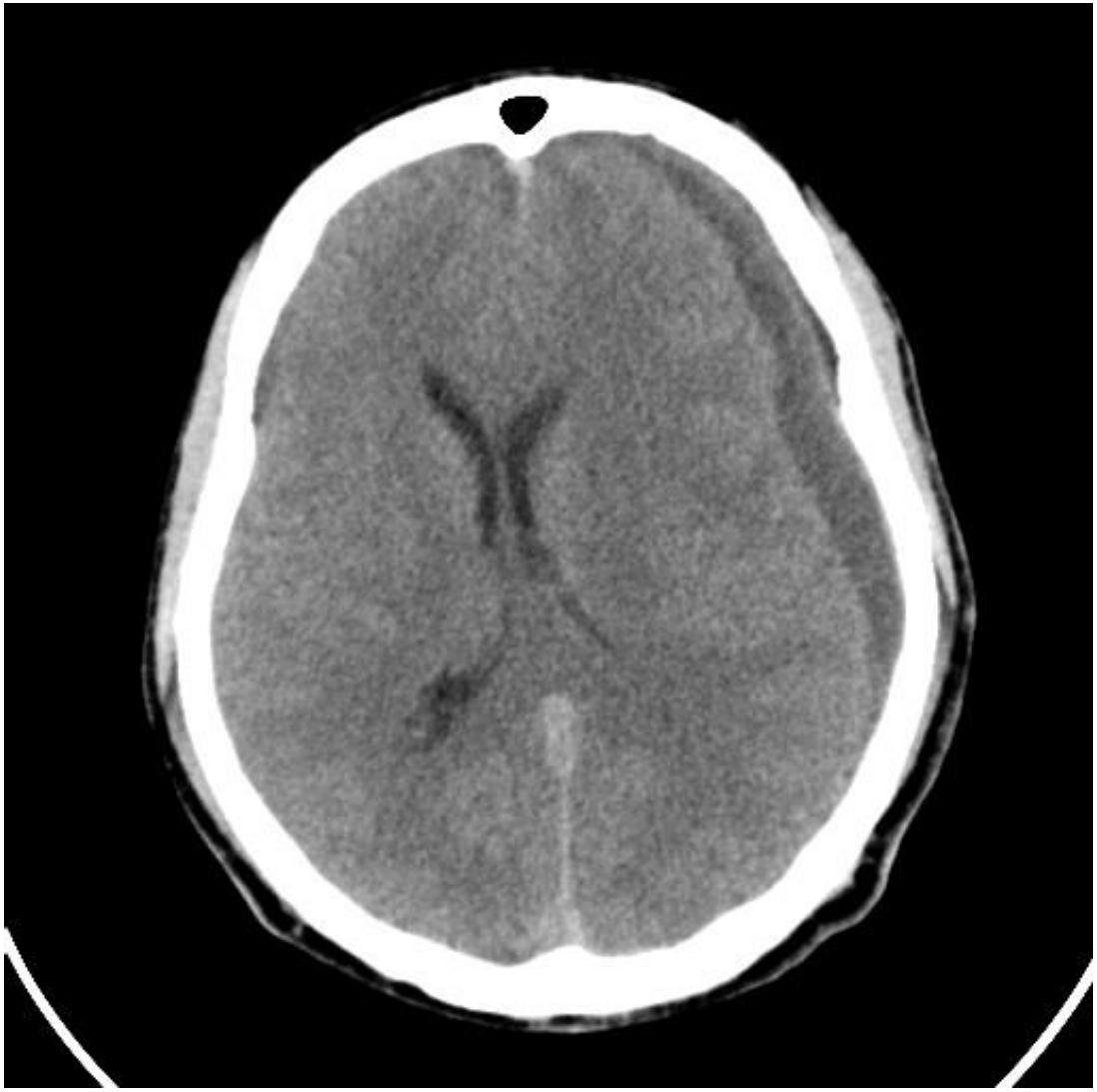

TBI-EDH

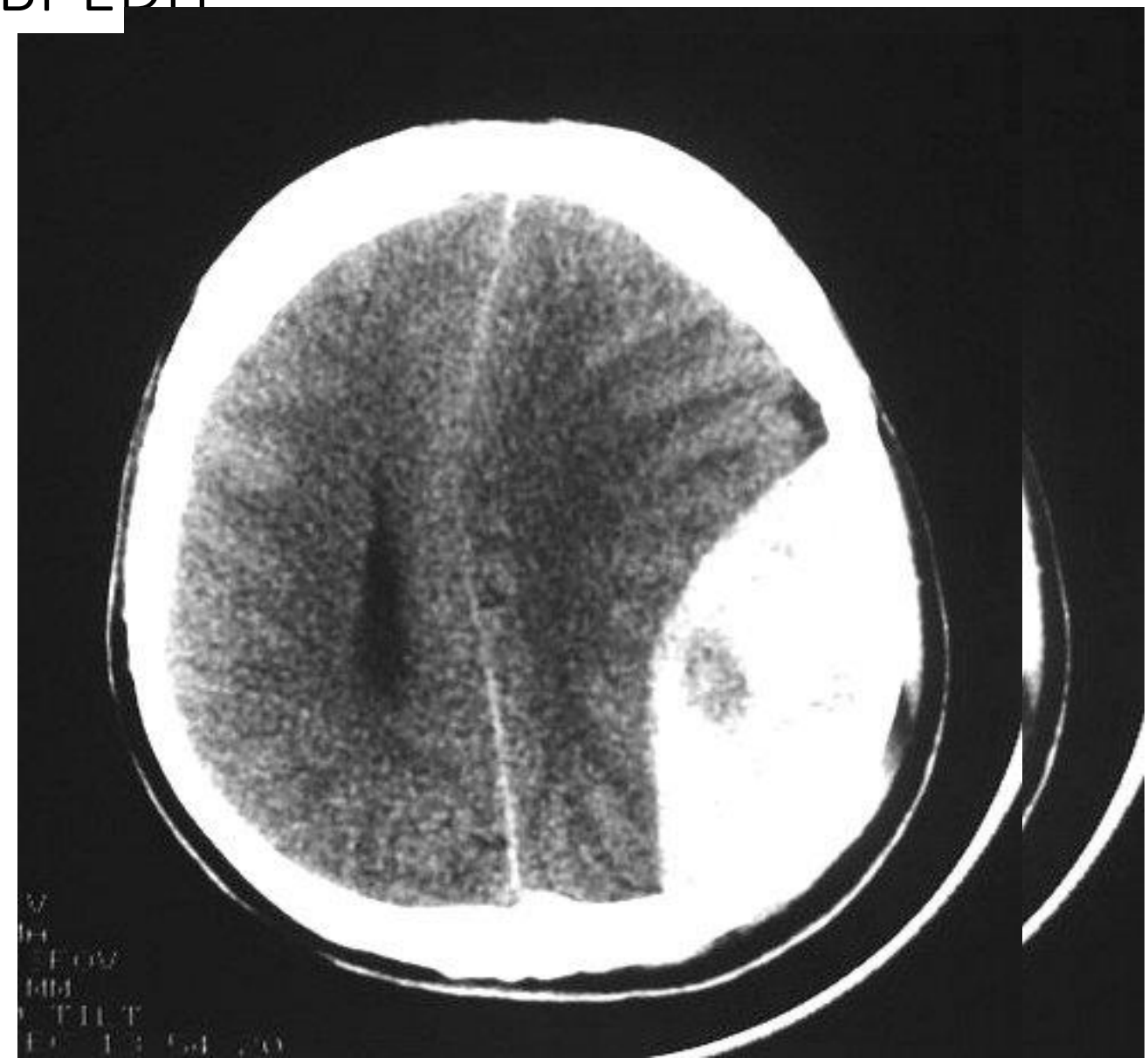

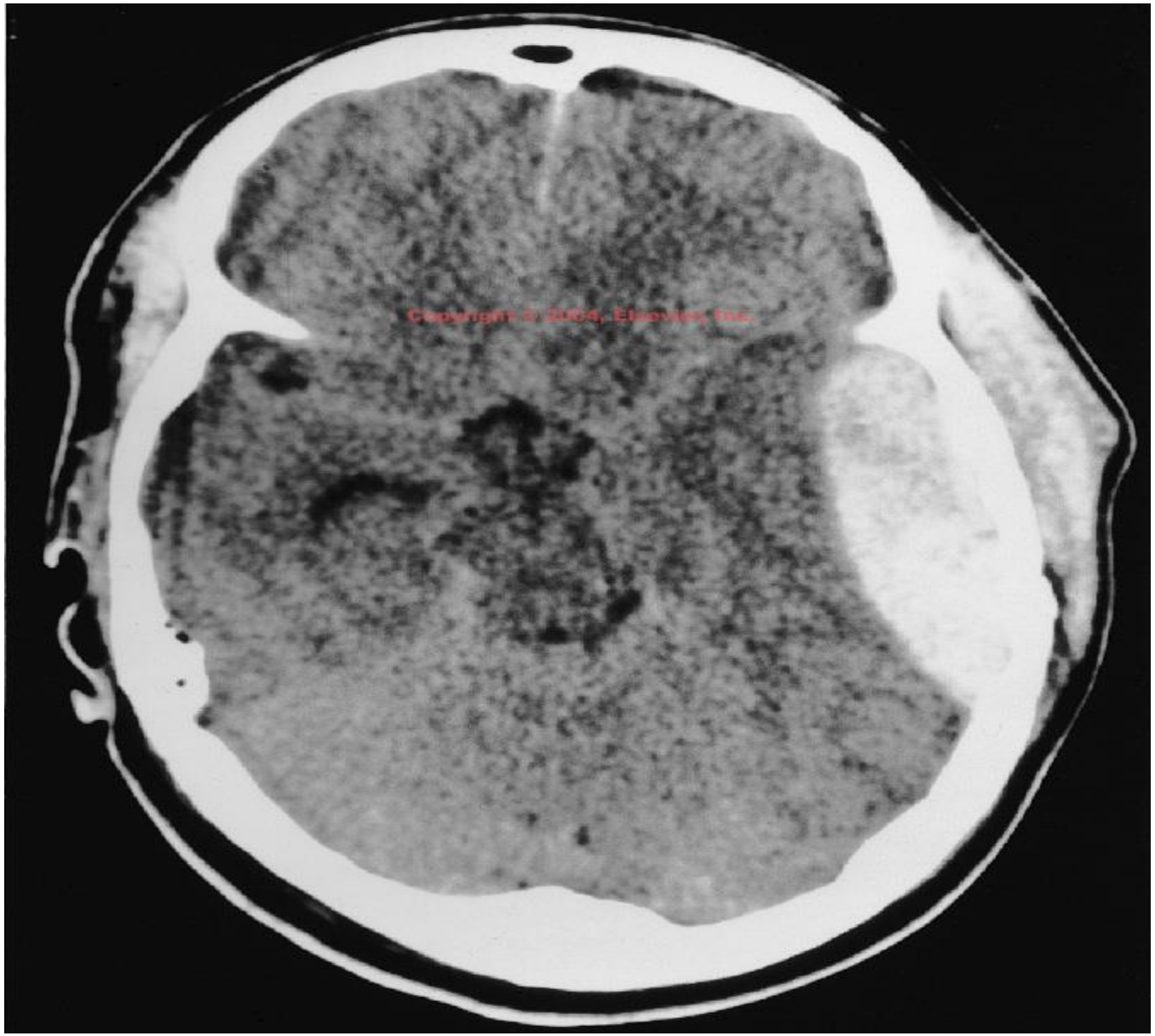
Copyright © 2004, Elsevier, Inc.

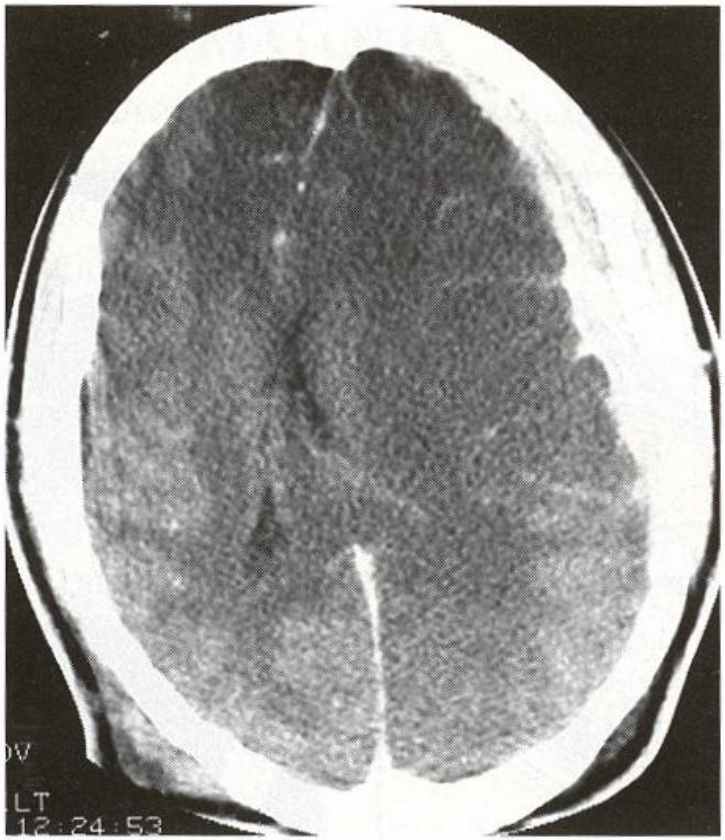

5. What intracranial bleed is represented on the CT scan?

Watter intrakraniale bloeding word op die RT skandering afgebeeld?

TBI-SKULL FRACTURE

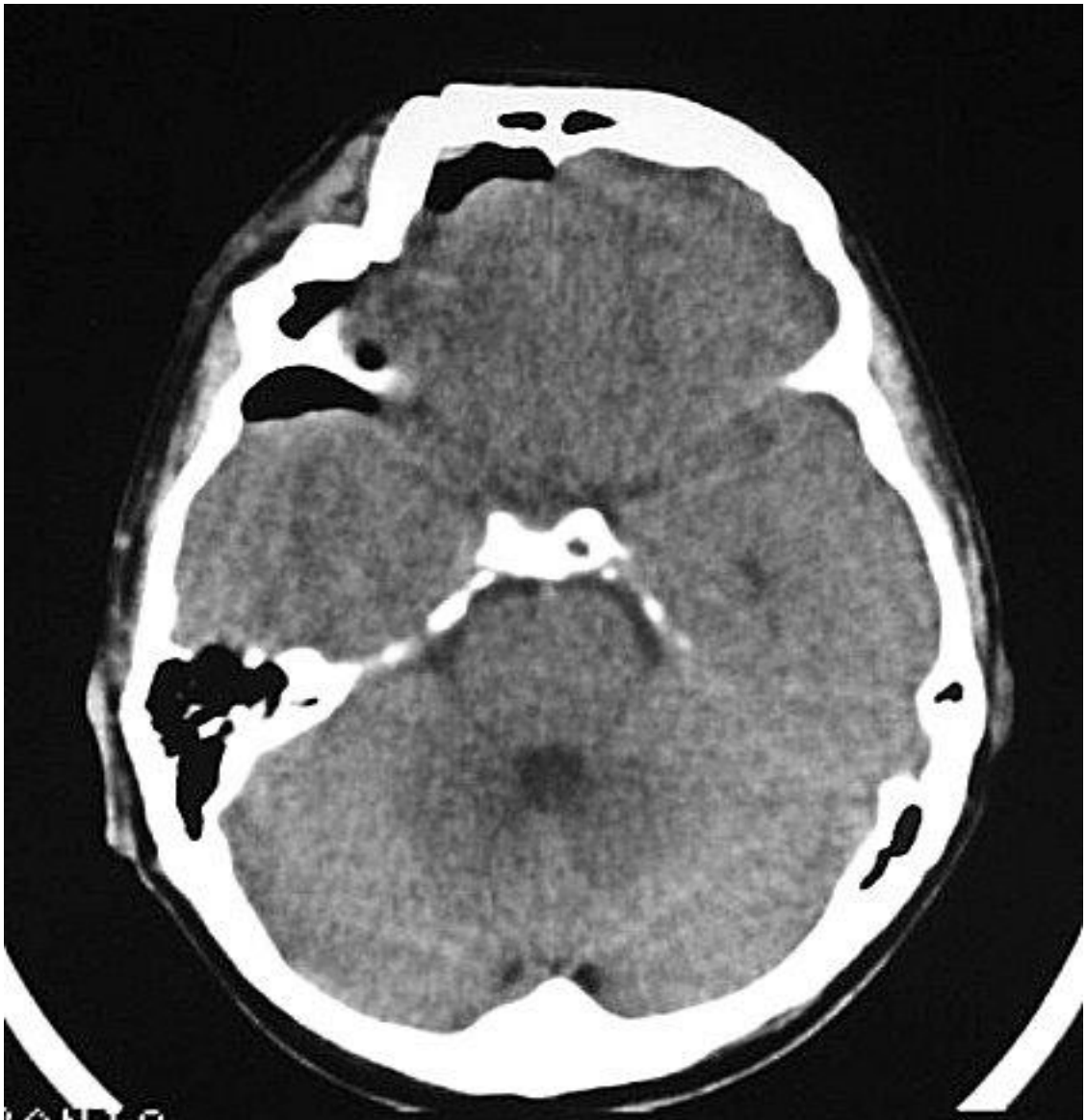

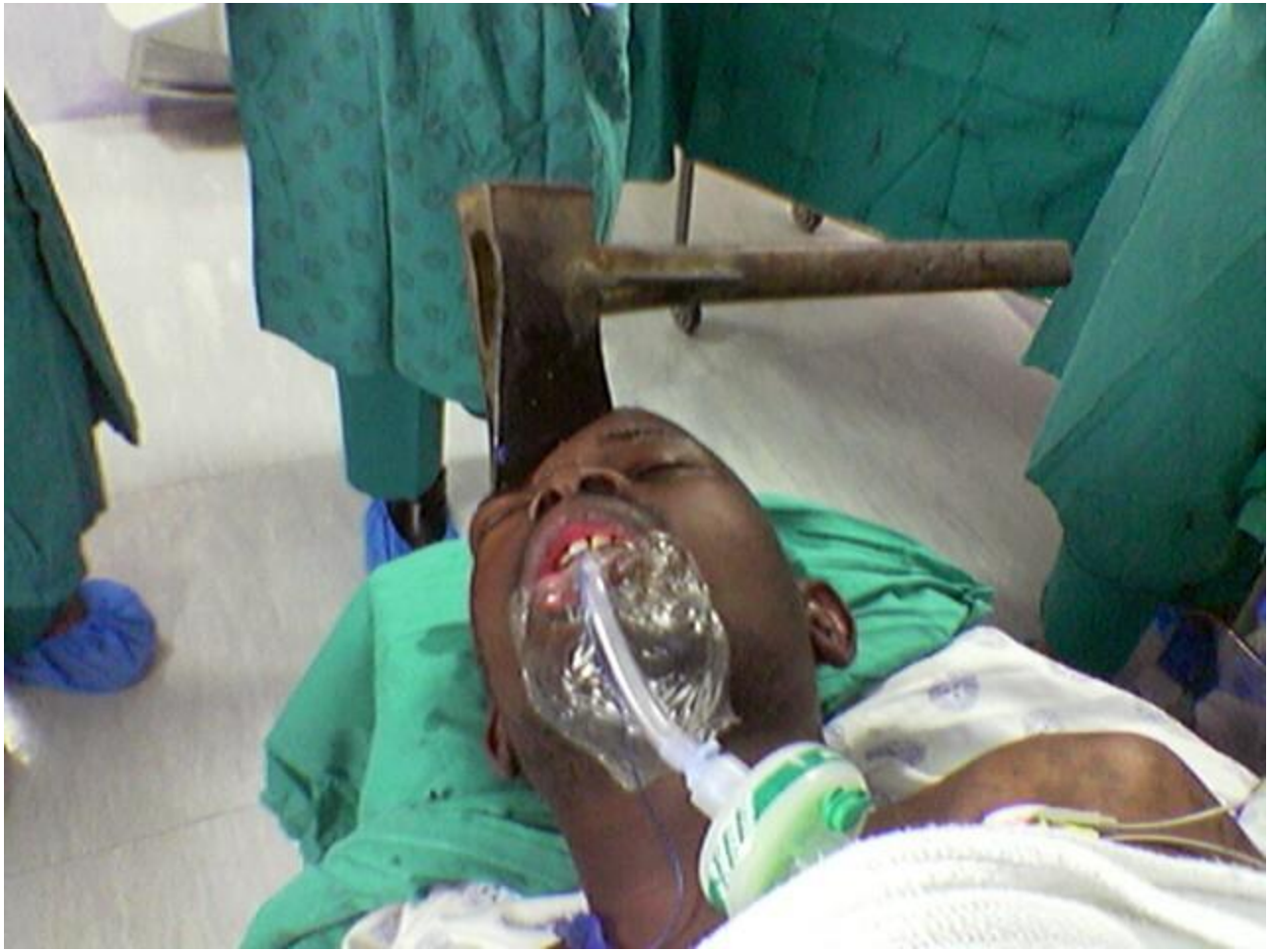

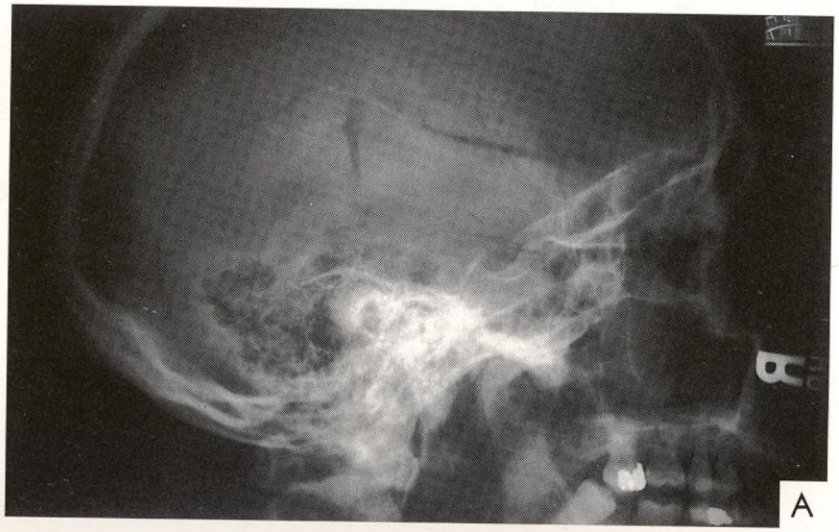

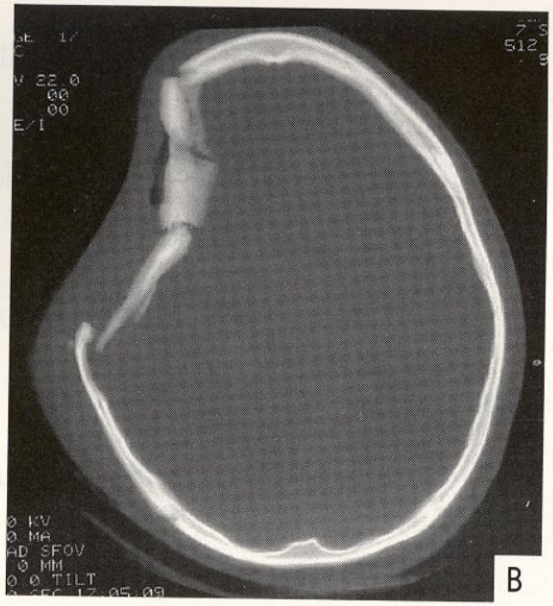

[redacted]

3. What is the diagnosis?

Wat is die diagnose?

Rengachary & RH Wi
Wolfe.1994

MANAGEMENT

This is after resuscitation (A, B, C….) and stabilisation.

(A) INVESTIGATIONS

-Skull X-rays: fractures to be elevated ±antibiotics.

-CT brain: e.g. intracranial haematomas to be evacuated.

-MRI scans: most advanced.

INITIAL MANAGEMENT OF A SEVERE HEAD INJURY – GCS ≤ 8

- RESUSCITATION

  - RESIRATORY SYSTEM AND C-SPINE PROTECTION
    - Intubate and ventilate to avoid hypoxia and hypercarbia

  - CARDIOVASCULAR SYSTEM
    - IV Fluids – Initially Ringers lactate or Normal saline
    - MAP 80-100mmgh
    - Avoid glucose containing solutions in the first 24hrs unless hypoglycaemic

  - CENTRAL NERVOUS SYSTEM (General Measures to control ICP)

    Elevate HOB to 30degrees

    Avoid constriction of the jugular veins

    Sedation and Analgesia
    - Midazolam (Dormicum)
      - 2 to 4mg/hr
    - Propofol (diprivan)

    - Morphine or fentanyl

    Anticonvulsants – phenytoin
      - LD: 18mg/kg
      - MD 100mg 8hrly

    Antibiotic prophylaxis as necessary

    Paralysis
    - Pancuronum
    - Vercuronium

    ICP monitoring

    Indications – See lecture on raised intracranial pressure

    Types – Extradural, Subdural, Intracerebral, Intraventricular.

SPECIFIC MEASURES TO REDUCE RAISED INTRACRANIAL PRESSURE

- Ventriculostomy and CSF drainage
- Mannitol and lasix
  - Mannitol is an osmotic diuretic and free radical scavenger
  - Dose: 0.25g/kg 6hrly IV
  - Monitor serum osmolality and maintain < 320mosm/kg to prevent renal failure.
- Paralysis
- Barbiturates eg. Sodium Pentobarbital
  - May cause hypotension
- Hyperventilation
  - Maintain PCO2 between 4 and 4.5kpa
- Steroids
  - No longer in use for head injuries.
  - No improvement in outcome
  - Risk of side effects
- Surgical evacuation of the intracranial haematoma
- Decompressive craniectomy

OUTCOME

- PREDICTORS OF OUTCOME

- GLASGOW OUTCOME SCALE
  - 5 Complete recovery
  - 4 Partially disabled
  - 3 Severly disabled
  - 2 Persistent vegetative state
  - 1 Died

- MORTALITY
  - Mild HI 0.4%
  - Moderate HI 4%
  - Severe HI 40%

- MORBIDITY
  - Sequelae or long term complications of a HI

(B) TREATMENT OF SEVERE HEAD INJURY

- Head end elevation (30°±) and head/ neck neutral position.
- Intubate for airway protection
- I/V line for fluid therapy, bladder catheter.
- Normalise $Pa0_2$ and $PaCO_2$
- Mannitol, 1-2g/kg/day for raised intracranial pressure.
- Start feeding on day $\geq$2 n/g feeds.

THANK YOU !!!