

Review Case of the week

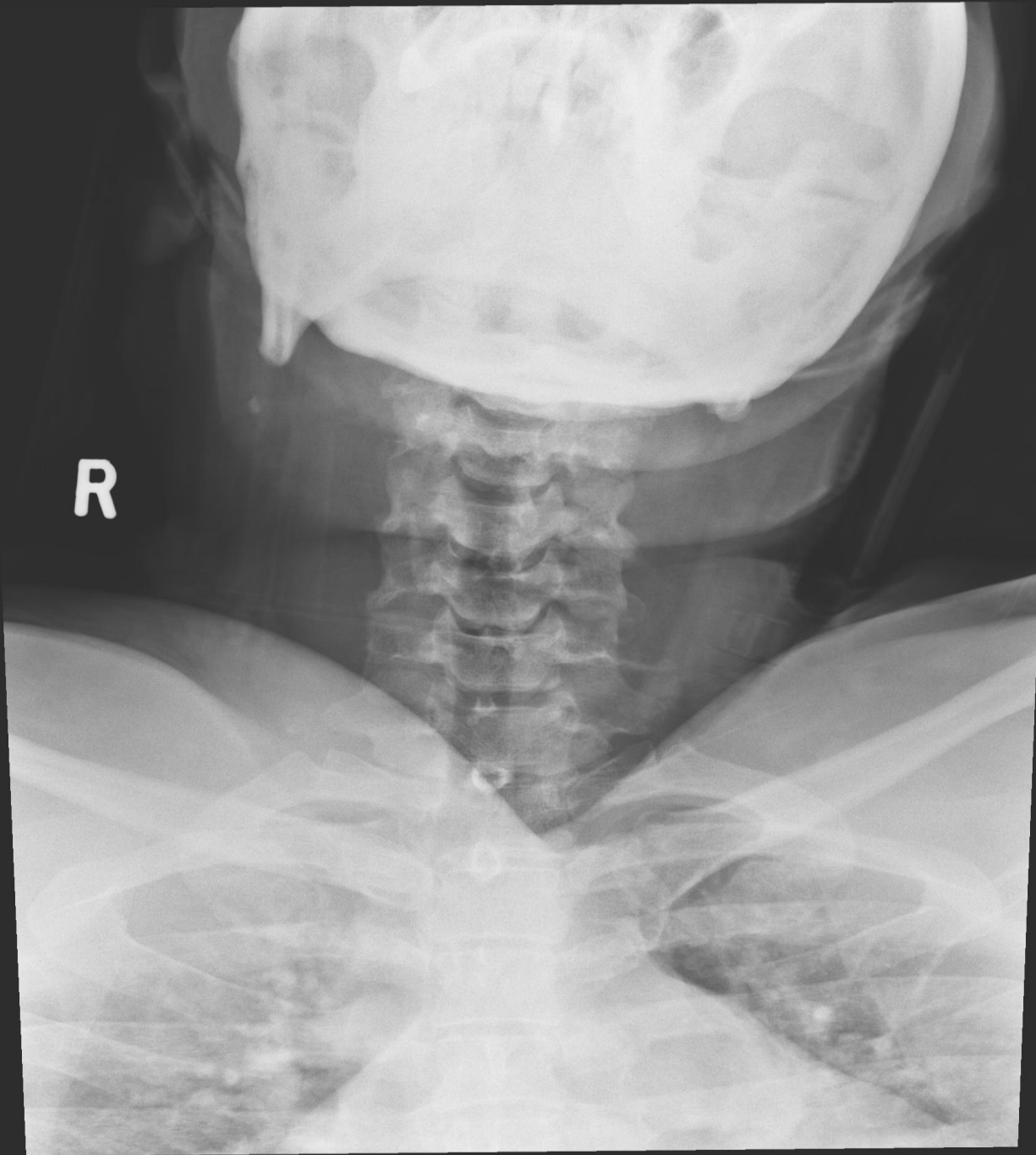
11 April 2013

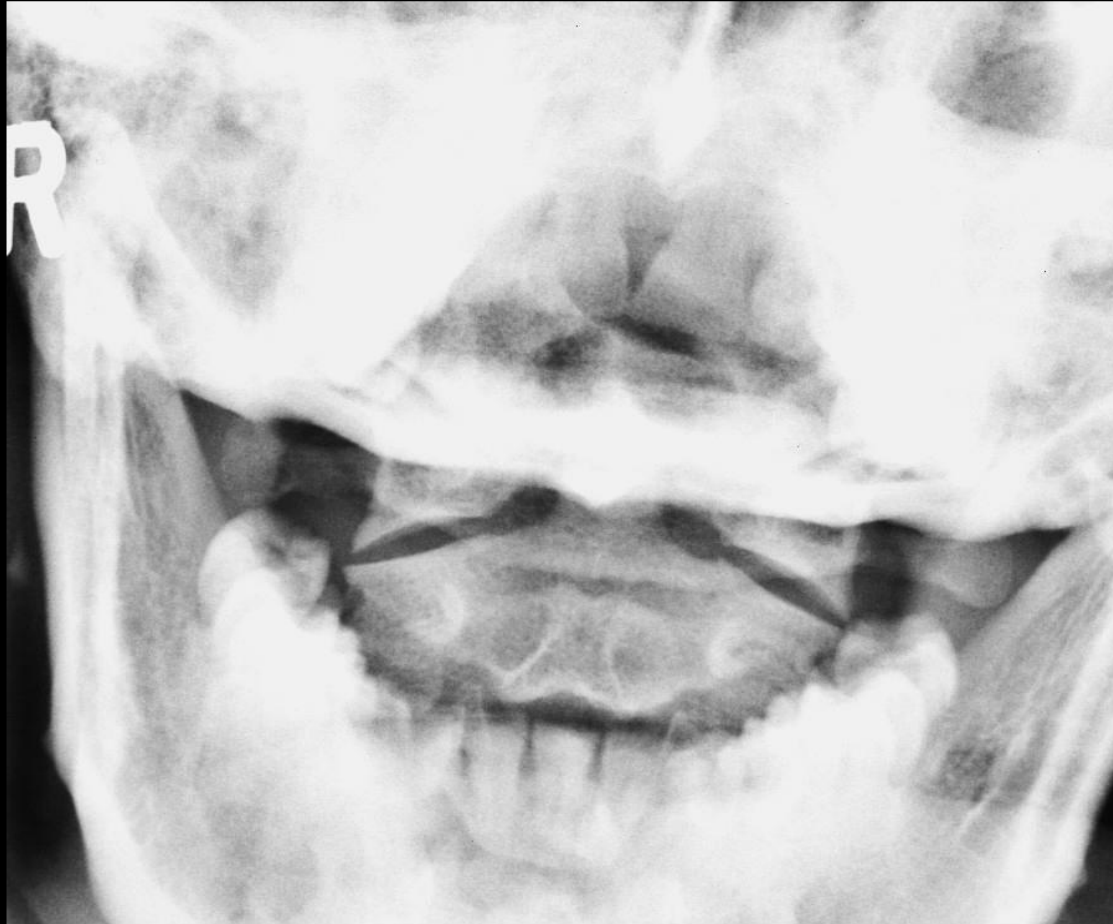Dr T G Kruger

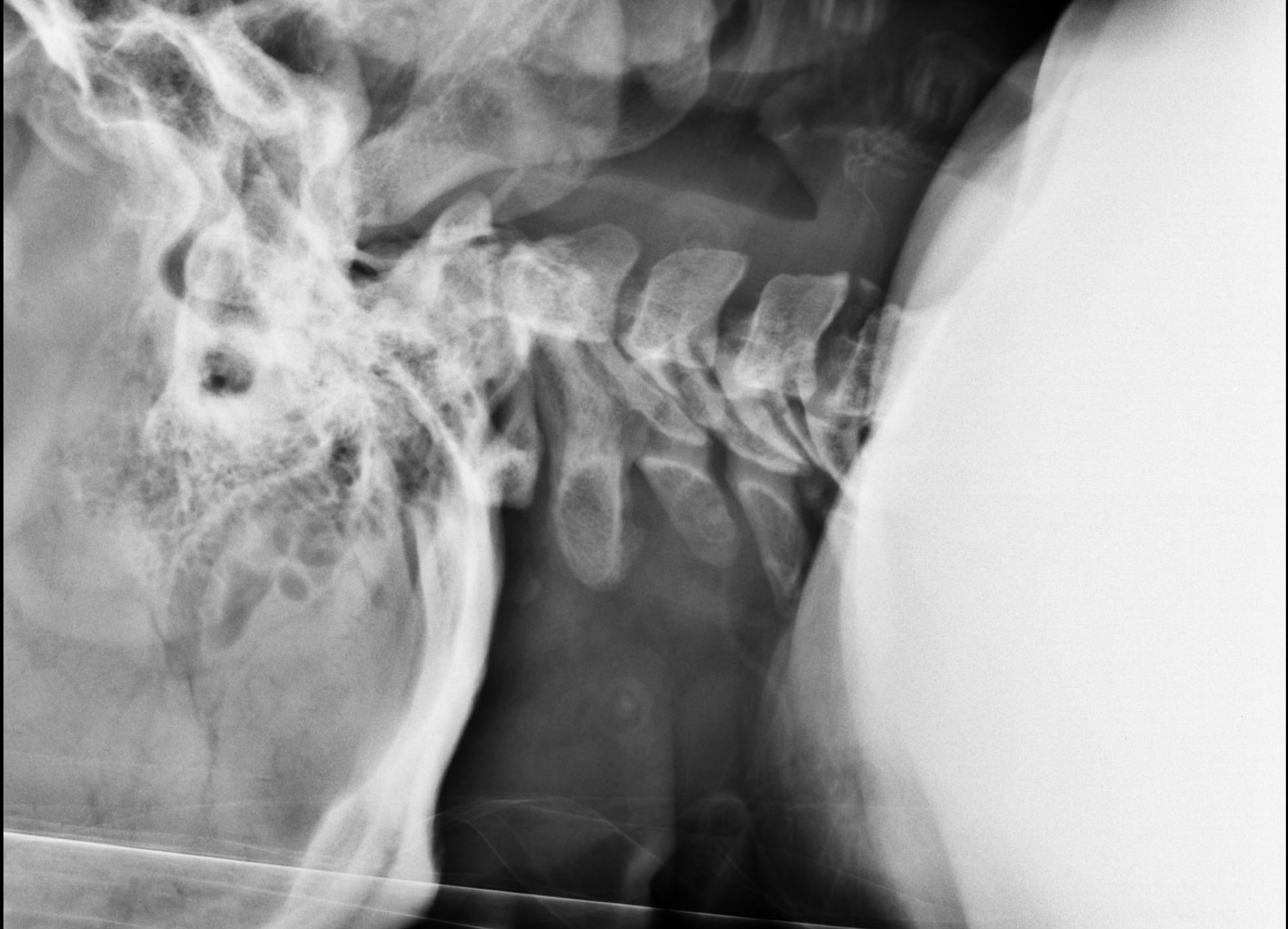Spinal Unit SBAH

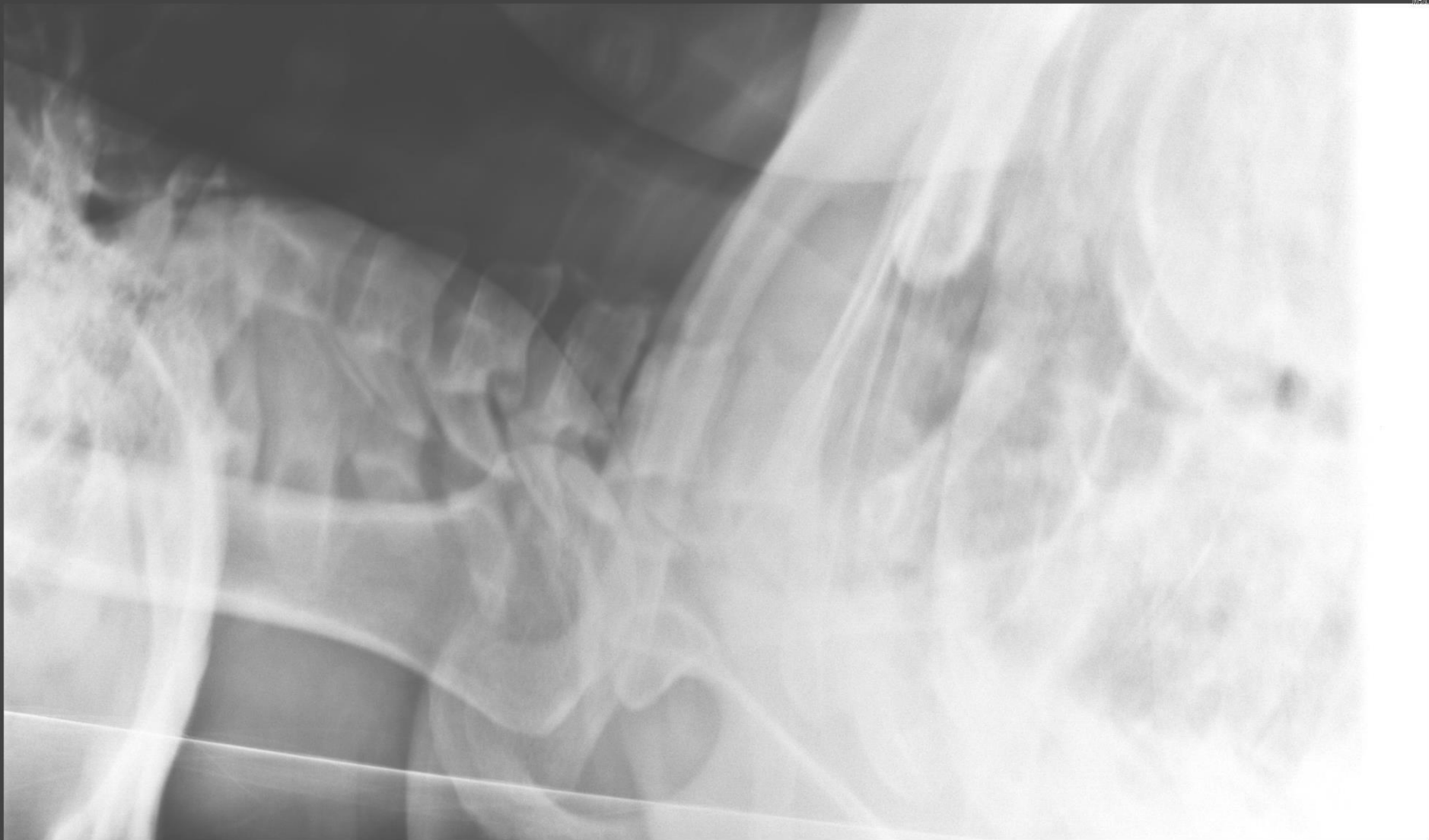Case 1

- 40 year old female
- MVA 08/04/2011
- Seen at other hospital – neck pain and unable to move L limbs
- Send home with no collar
- Admitted to SBAH on 10/04/2011
- Neck pain and L hemiparesis
- GCS 15/15, no head injury









MEDCOM RESAMPLED
[H]

Se:603
Im:18

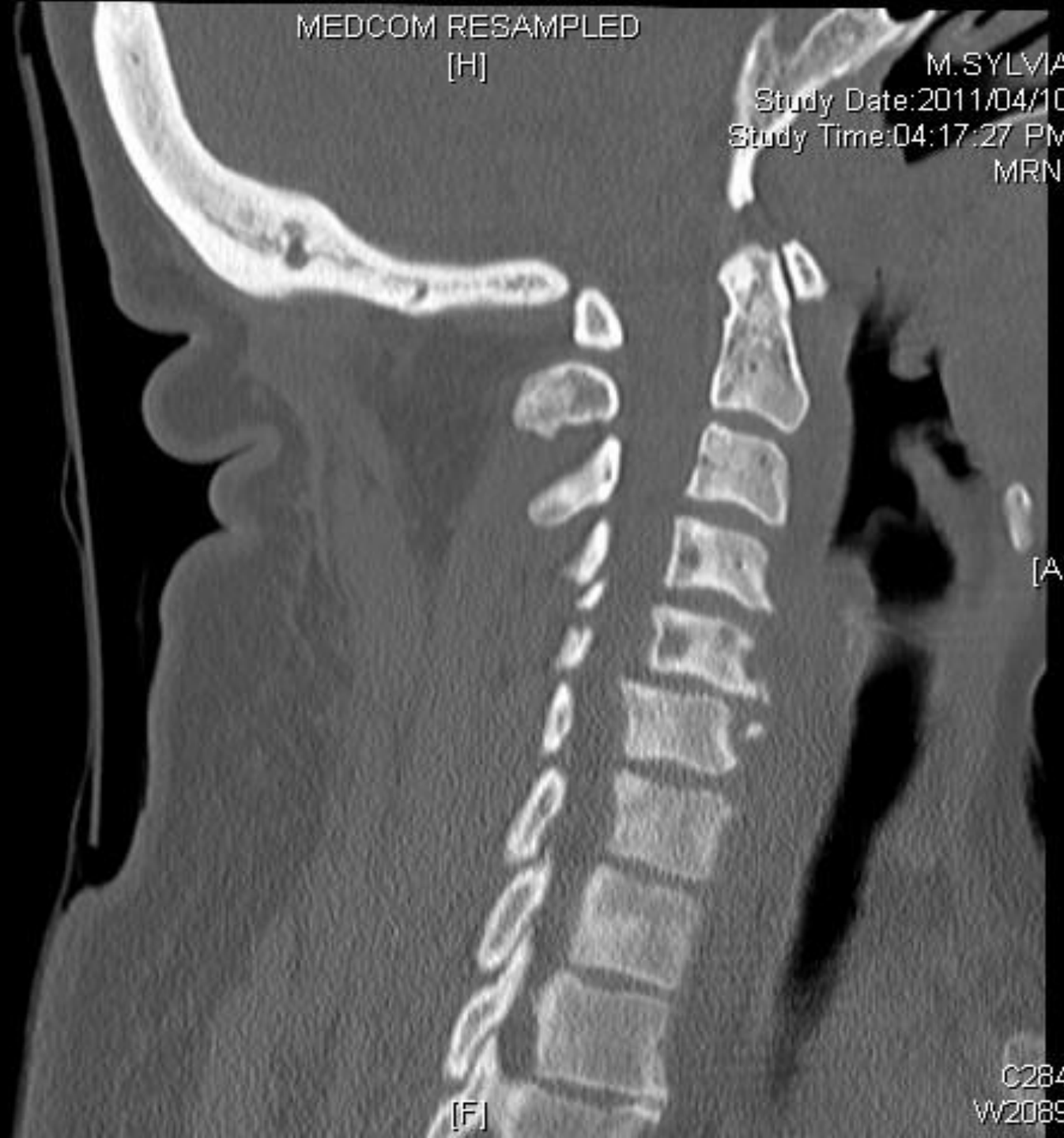M. SYLVIA
Study Date:2011/04/10
Study Time:04:17:27 PM
MRN:

[P]

[A]

[F]

C284
WV2089



Se:603
Im:23

MEDCOM RESAMPLED
[H]

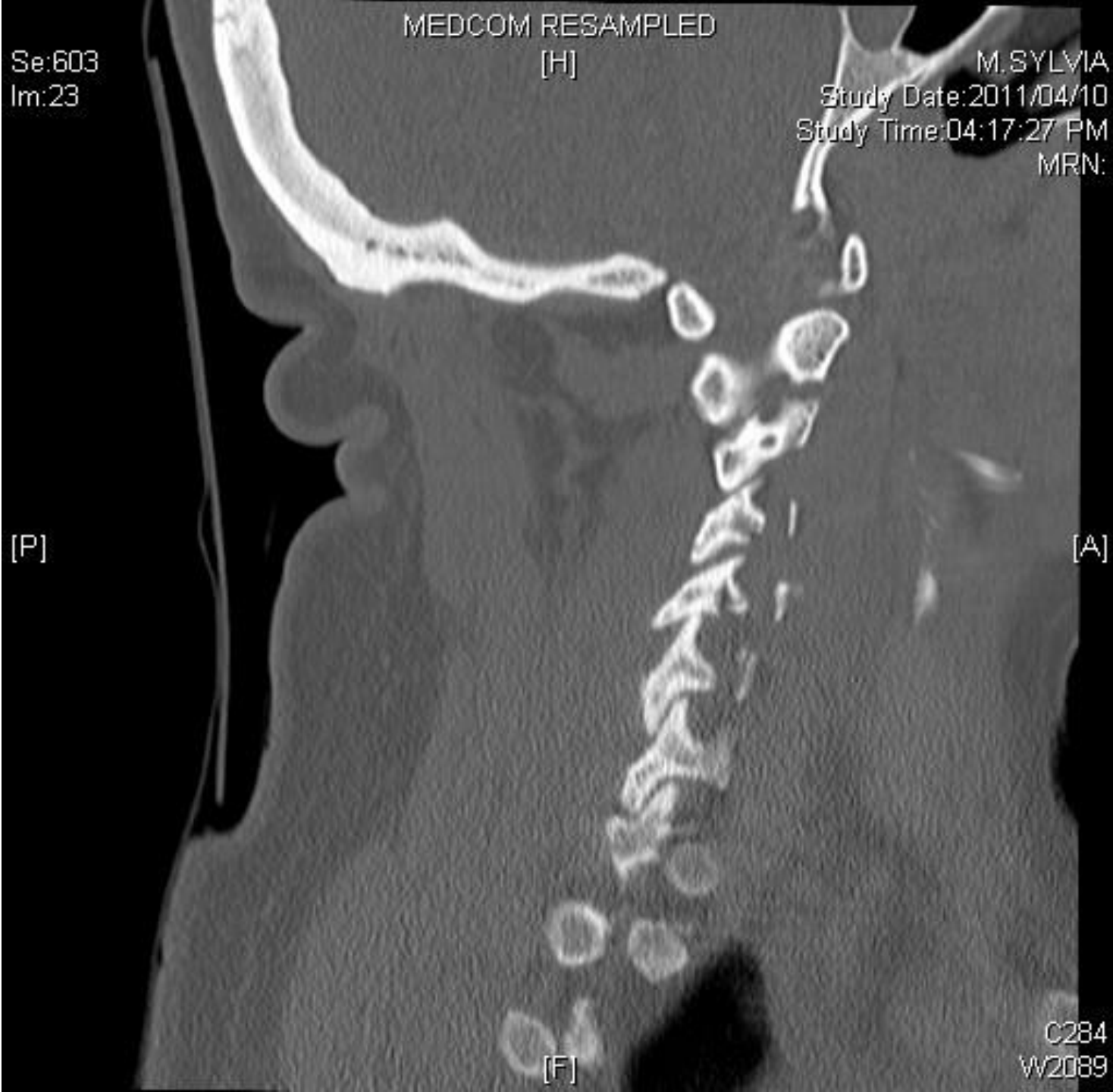
M. SYLVIA
Study Date:2011/04/10
Study Time:04:17:27 PM
MRN:

[P]

[A]

[F]

C284
WV2089



Se:901
Im:9

[HA]

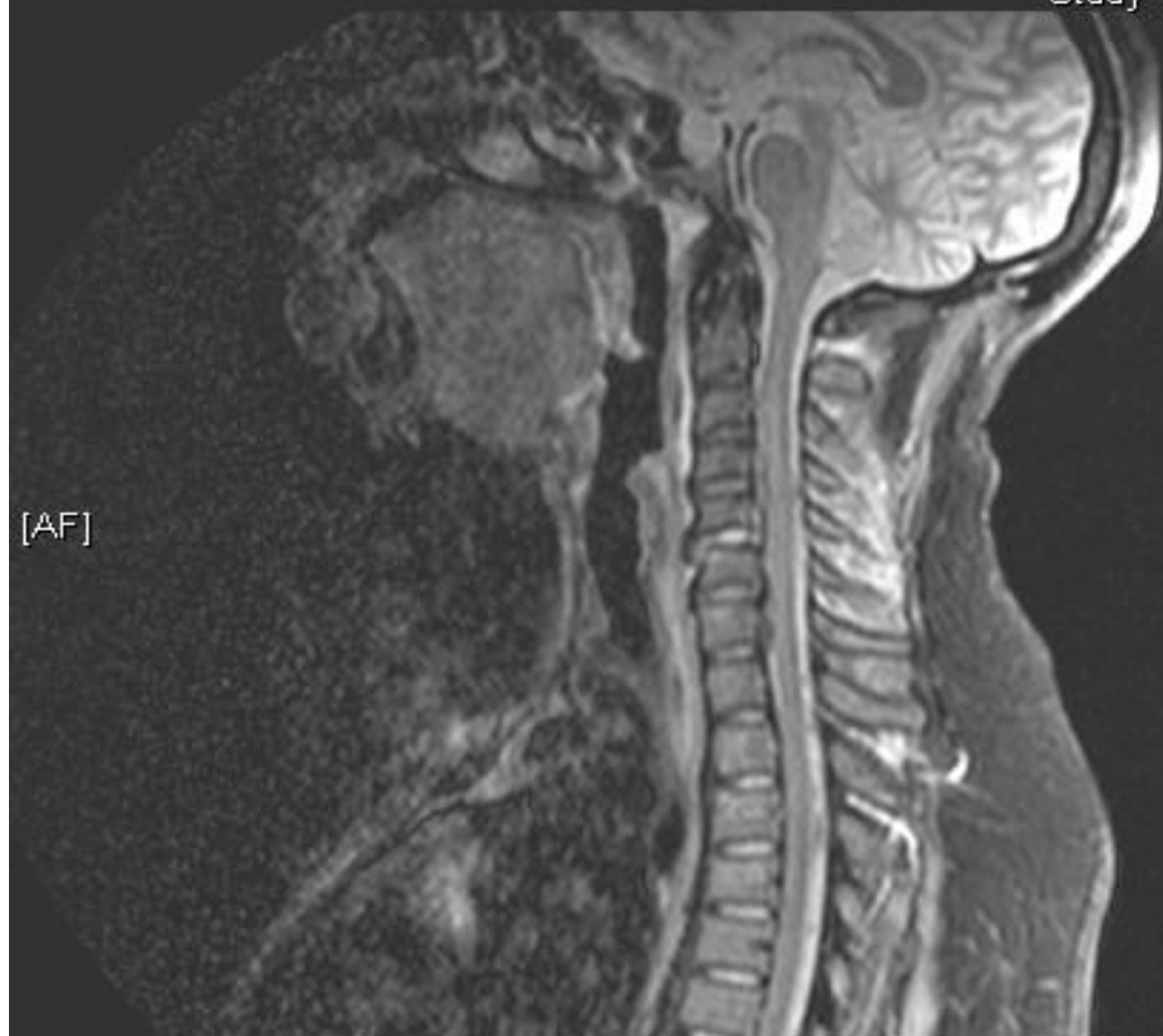
M.SYLVIA
Study Date:2011/04/11
Study Time:11:25:37 AM
MRN:

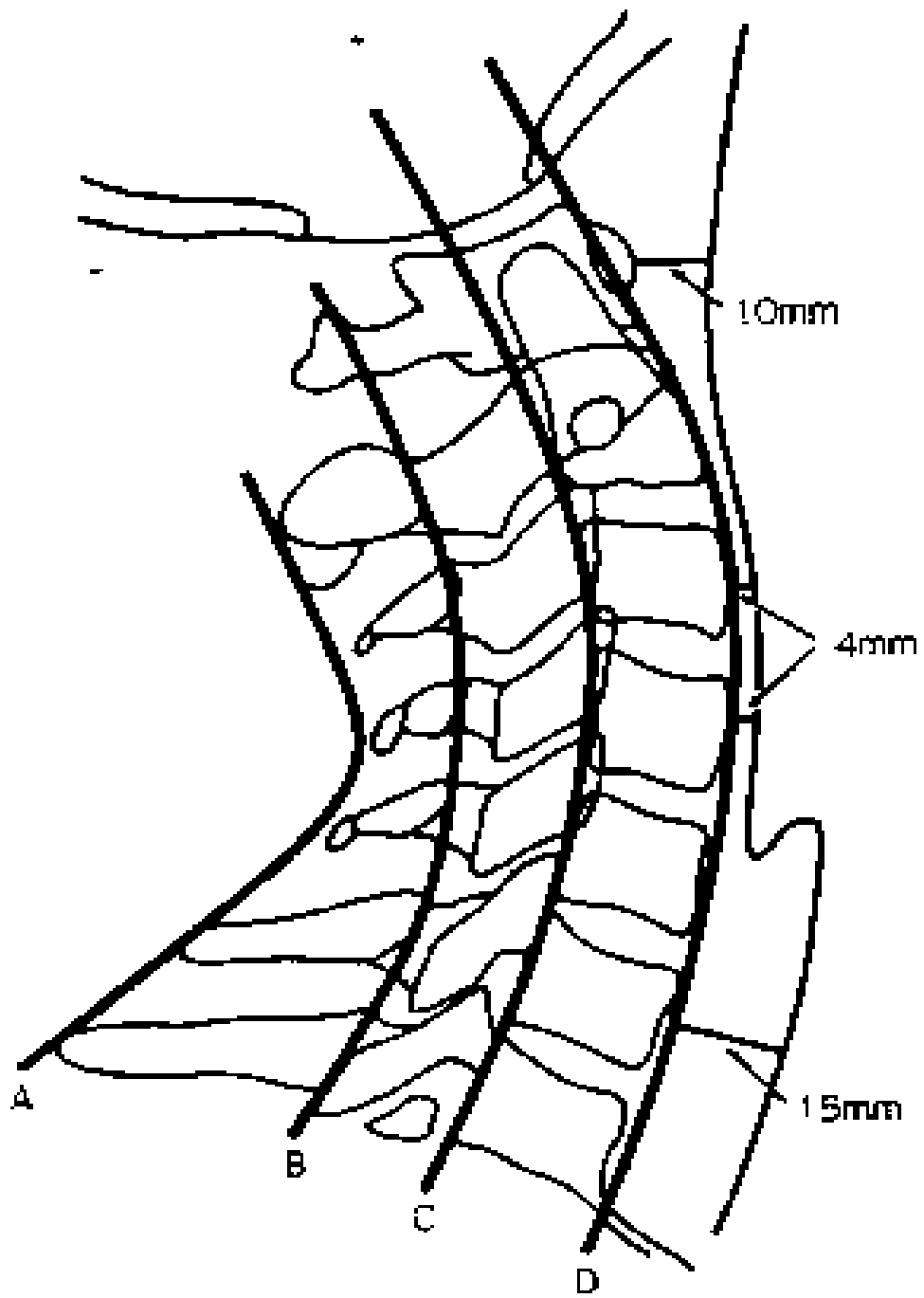
[AF]

[PH]

[FP]

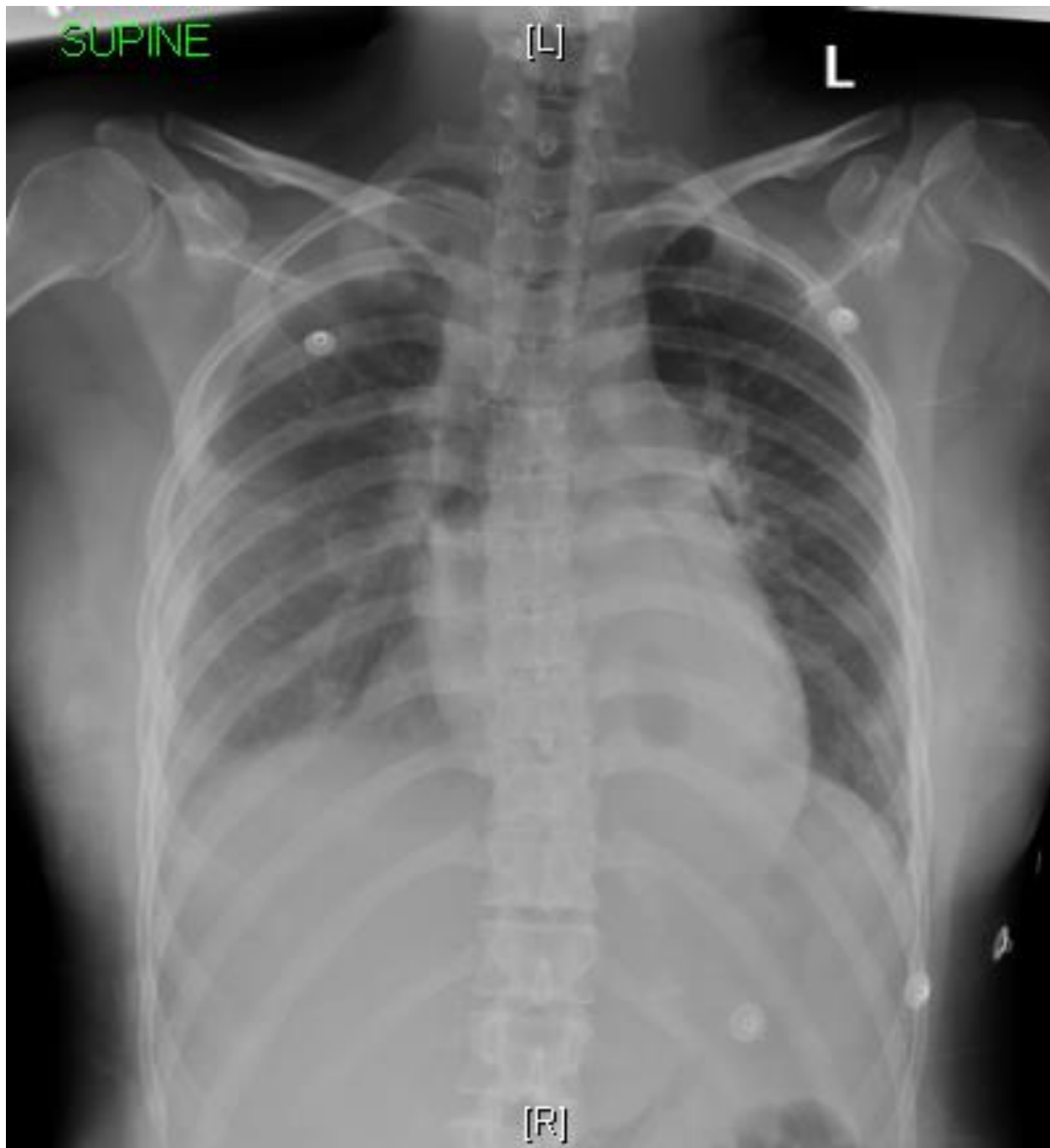
C286
W935

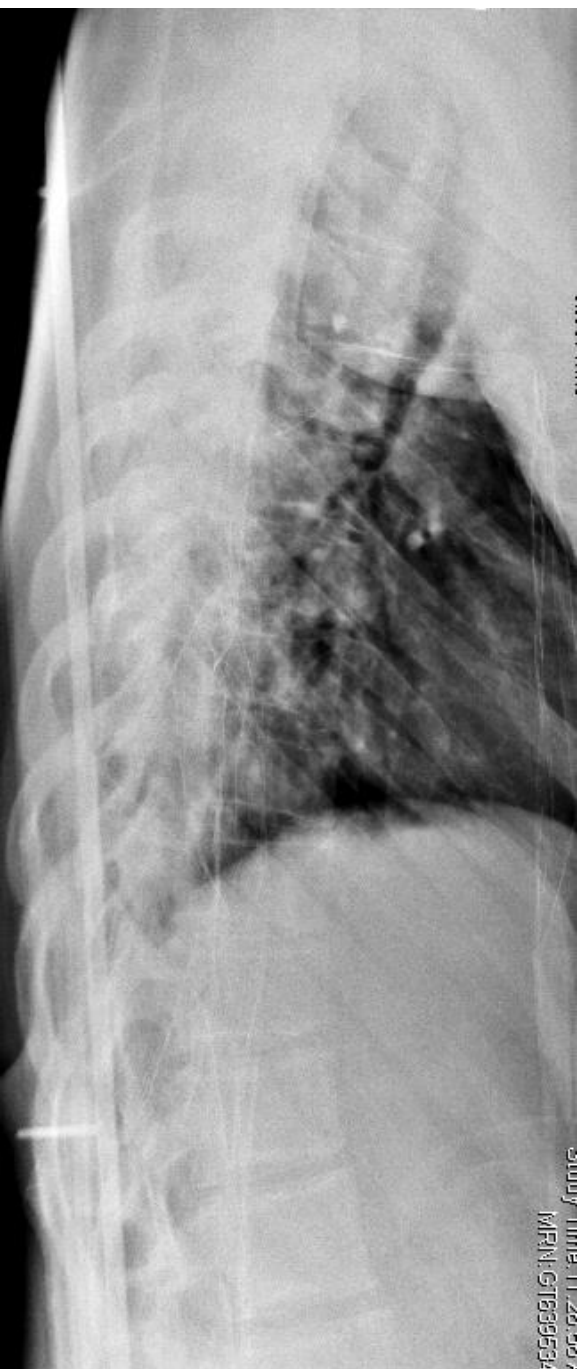
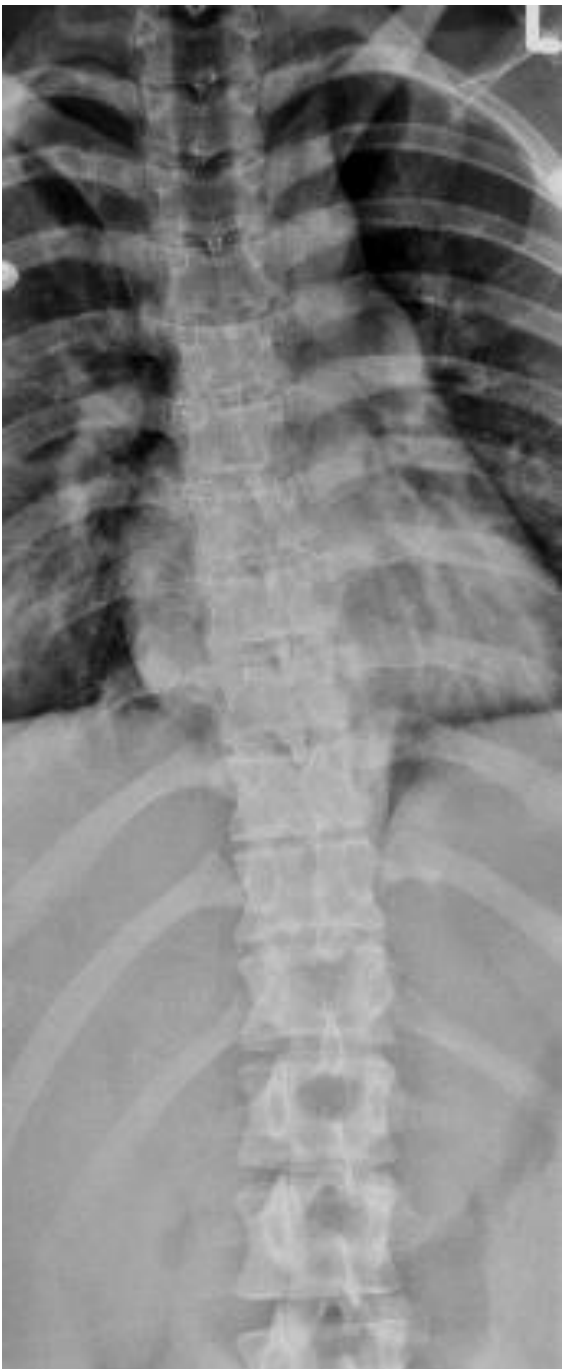


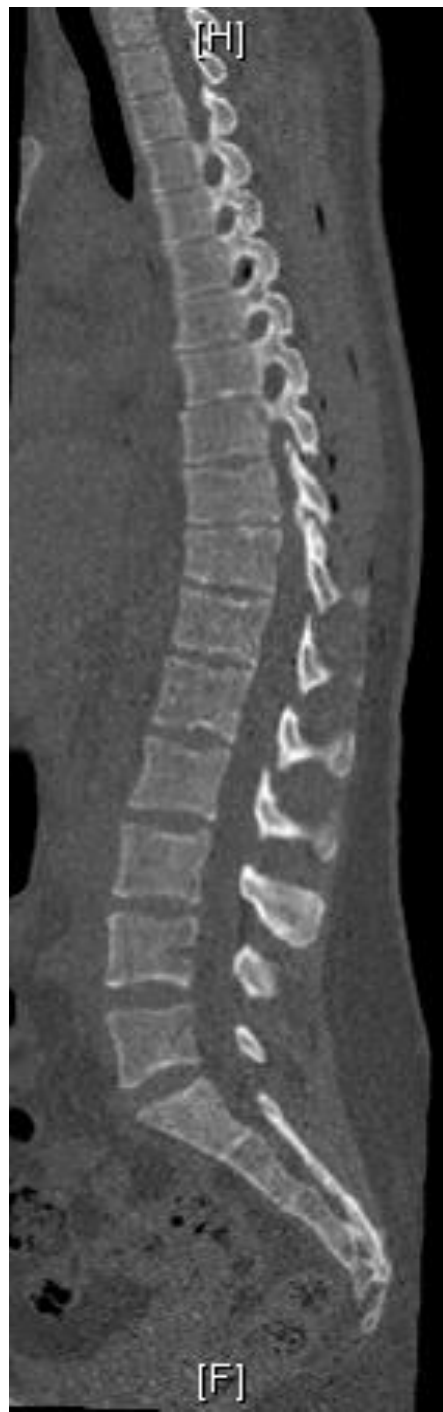
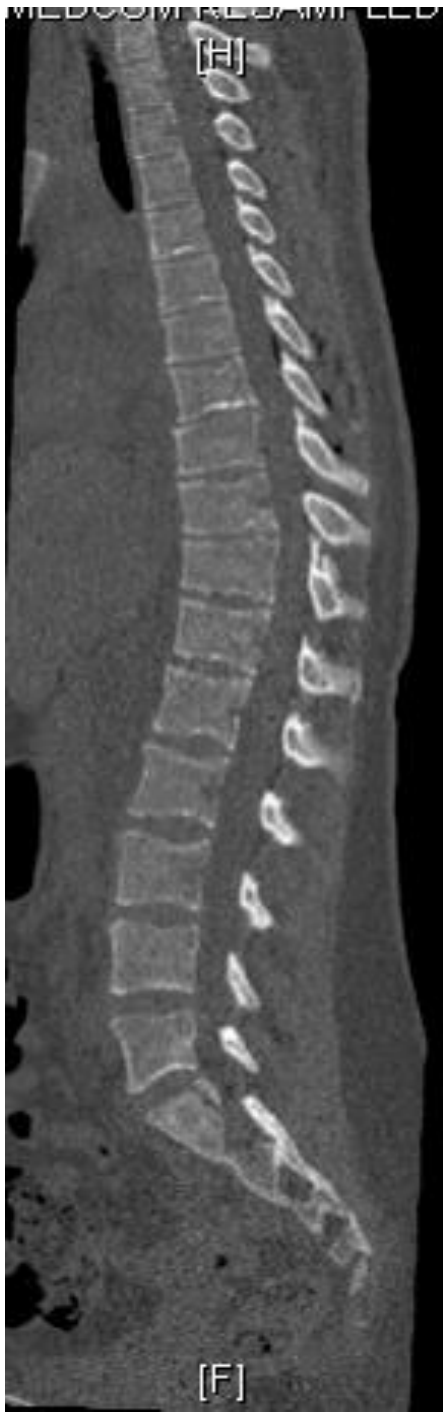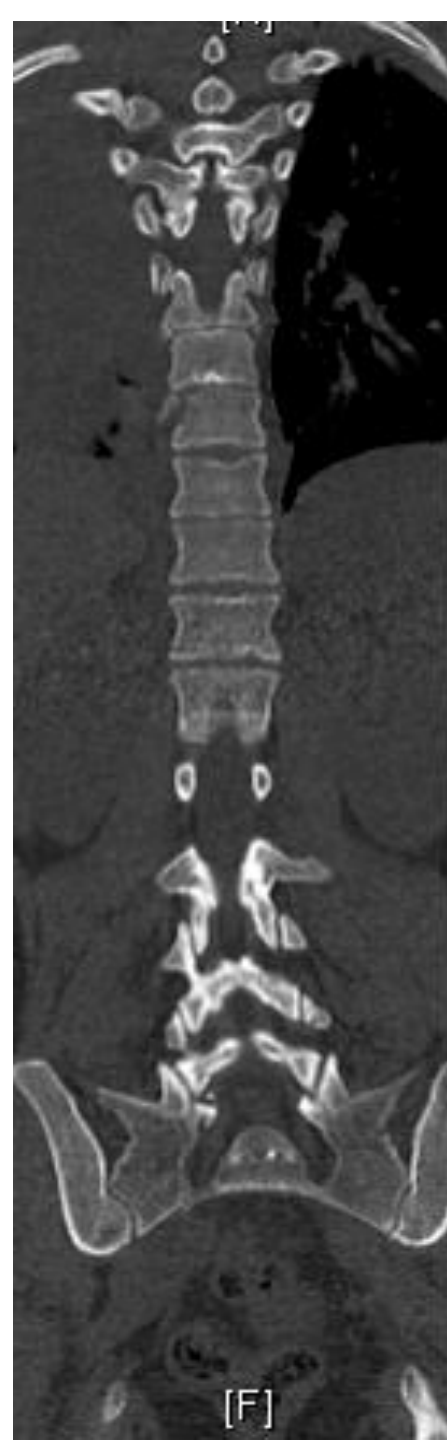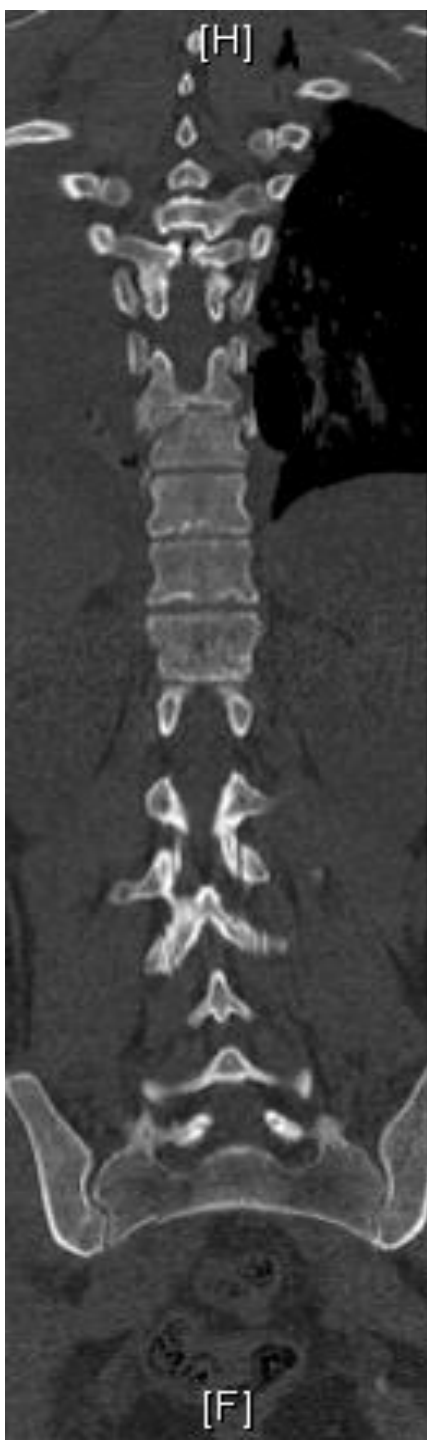Case 2

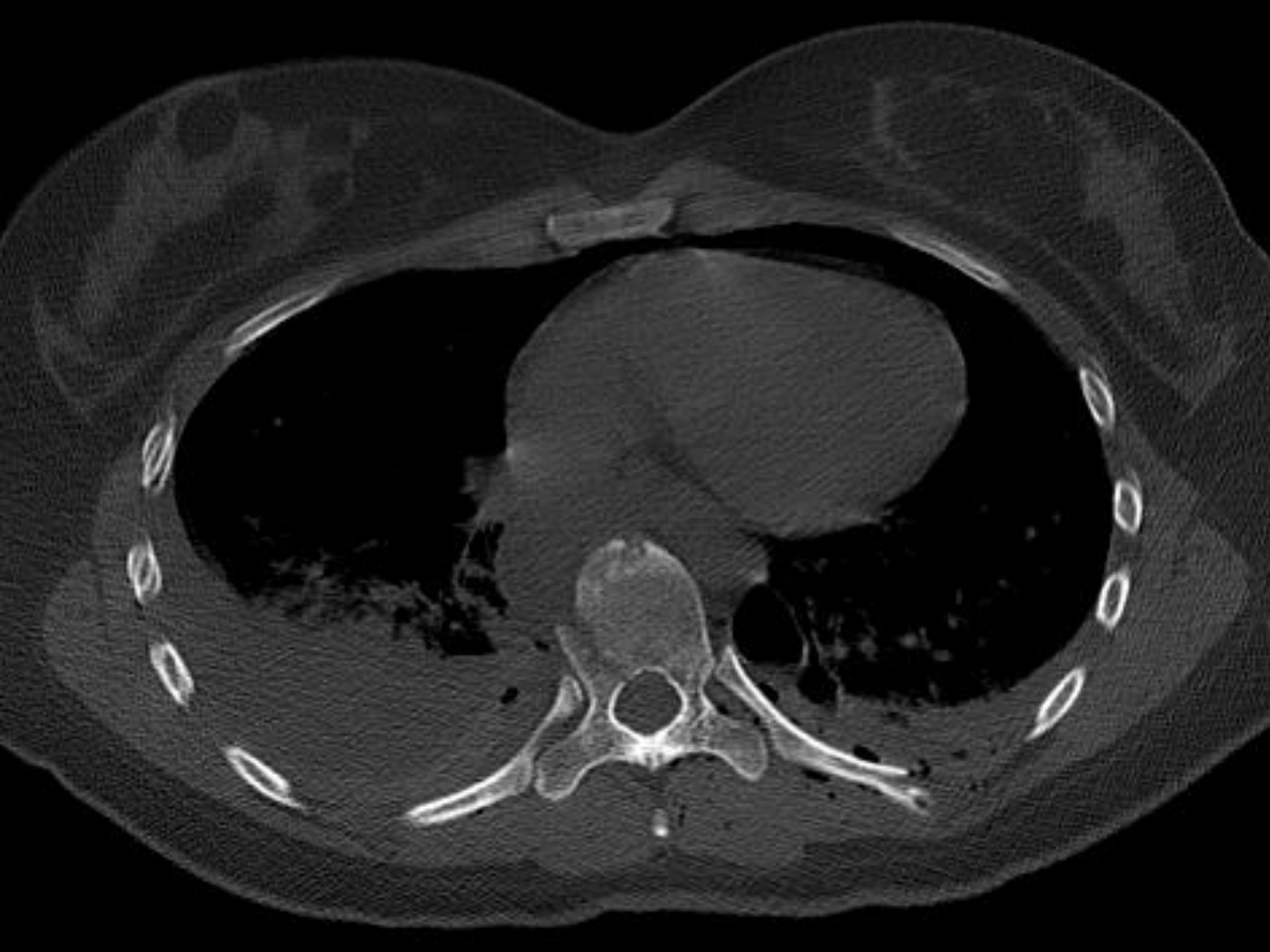
- Female - 21 years old
- Dropzone + Friday night
- MVA – driver killed
- Chest pain
- Unable to move legs

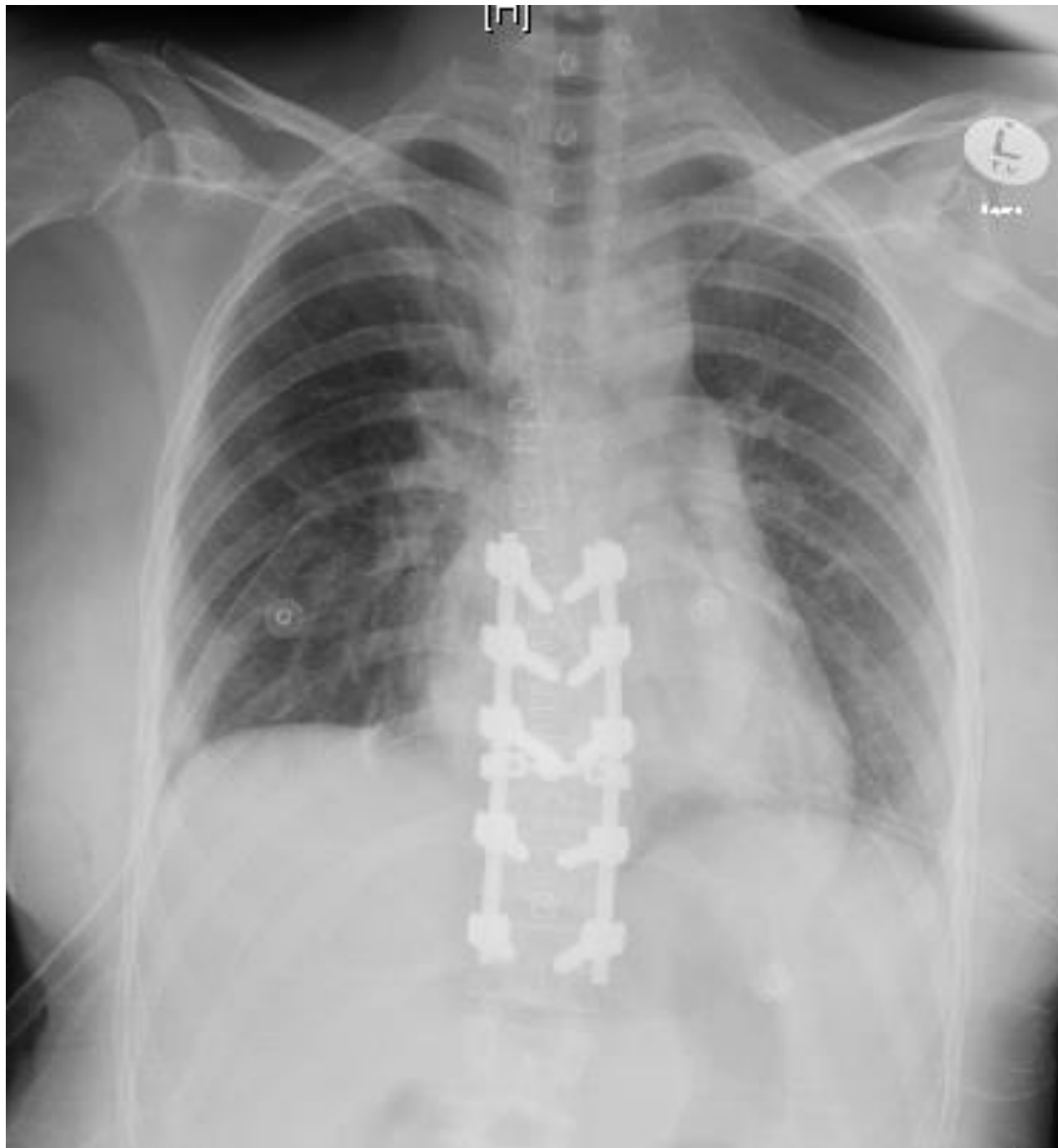











Thank You!