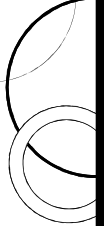


The paediatric chest xray

Salome Abbott
7-2-2012

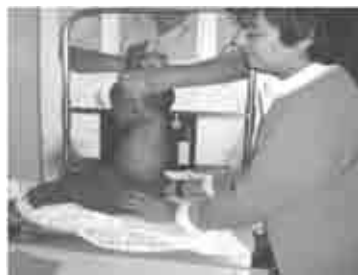
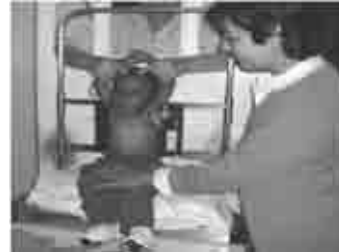
Overview

- Introduction
- Technical factors
- Differences from the adult xray
- Systematic review

Introduction

- Name, date, age
- Types of chest xrays
 - Frontal
 - Lateral

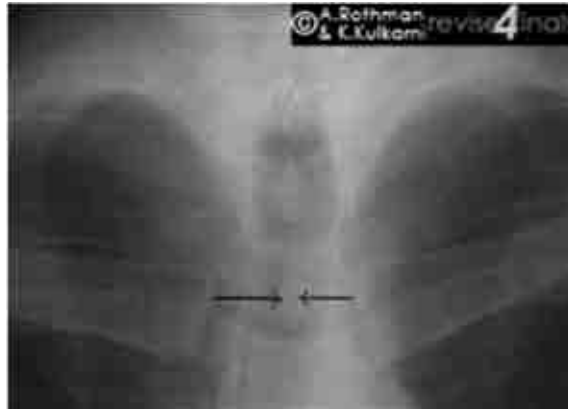

Technical factors

- Rotation
- Lung volumes
- Penetration

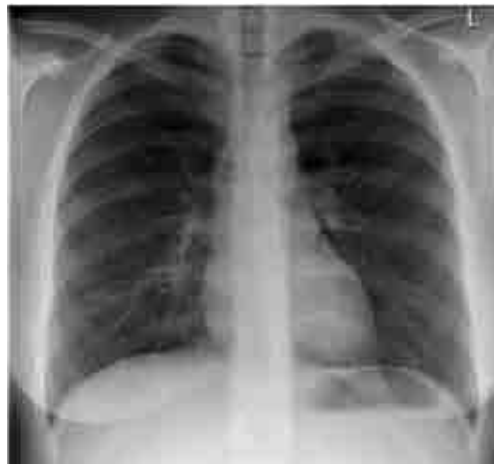Rotation

- Distance between medial end of clavicle and spine



Lung volumes

- Adequate 6 anterior ribs



Penetration

- Lucency of ribs till middle of xray

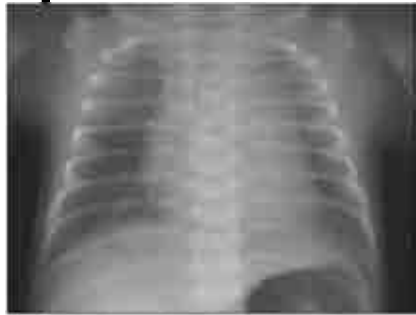
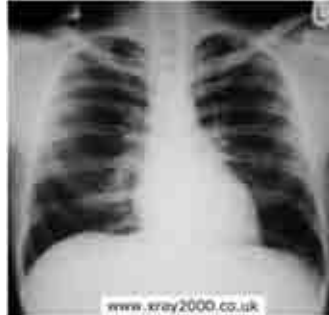
Figure 1. Normal chest x-ray of a two year old newborn infant, in compliance with technical standards.

Overpenetrated



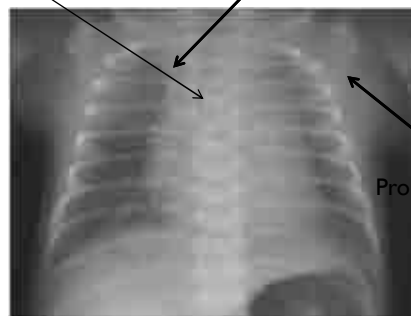
www.xray2000.co.uk

Underpenetrated

Differences from the adult xray

Trachea deviation to right

Wide mediastinum

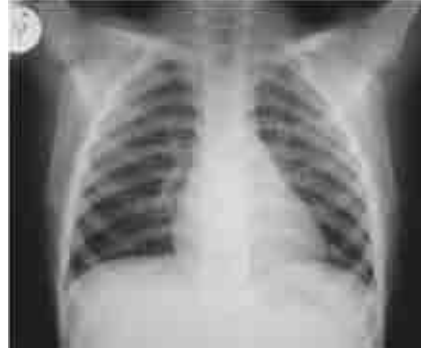

Prominent soft tissue

Figure 1. Normal chest x-ray of a two year old newborn infant, in compliance with technical standards.

Systematic review

- Trachea, bronchi
- Lung fields
- Mediastinum
- Heart
- Hemidiaphragms
- Foreign body
- Subdiaphragmatic region
- Other – bones

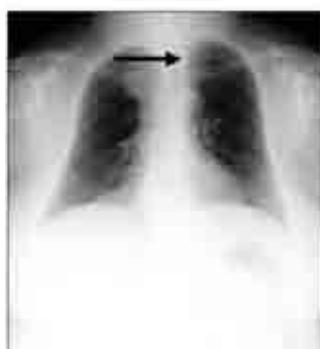
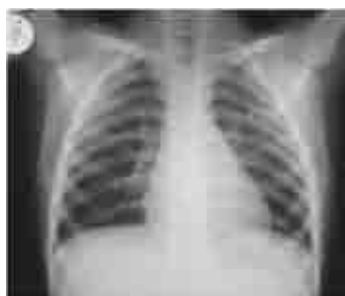

Systematic review

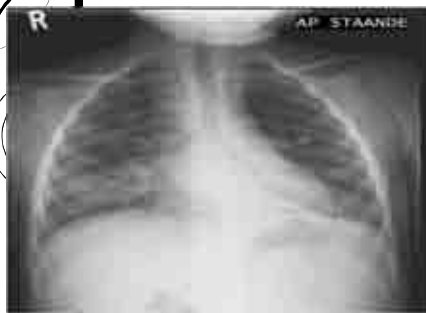- Trachea, bronchi
- Lung fields
- Mediastinum
- Heart
- Hemidiaphragms
- Foreign body – includes ETT, central lines
- Subdiaphragmatic region
- Other – bones

Trachea, bronchi

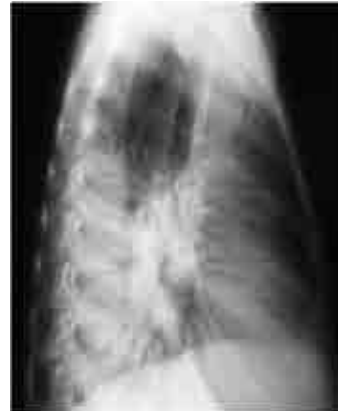- Position of trachea slightly to right is normal
- Splaying of corina $> 45^\circ$
- Hilar fullness
 - Enlarged lymph nodes
 - Tumours



Tracheal deviation to left



Splaying of corina



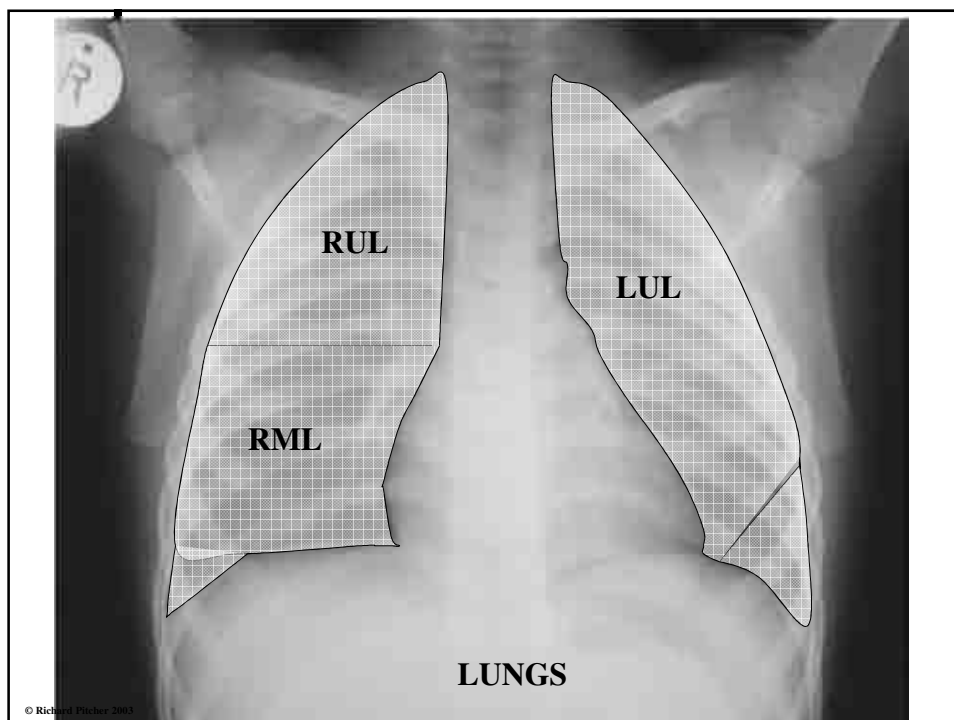
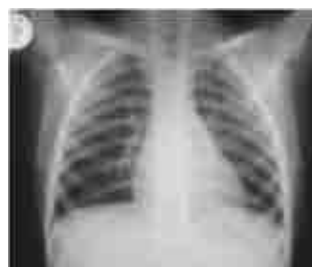Hilar fullness on lateral

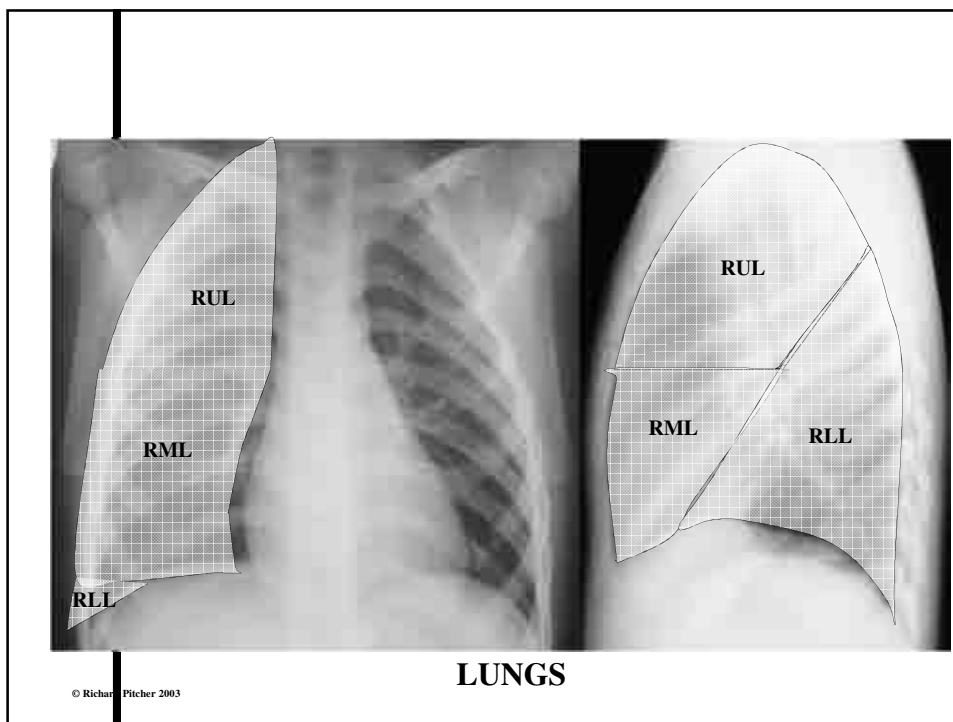
Systematic review

- Trachea, bronchi
- Lung fields
- Mediastinum
- Heart
- Hemidiaphragms
- Foreign body – includes ETT, central lines
- Subdiaphragmatic region
- Other – bones

Lung fields

- Lung markings, check from apices down
- Oligoemic/polygaemic
- Divide lungs into zones
- Compare both sides
- Fewer lung marking on peripheries
- Look for pneumothorax





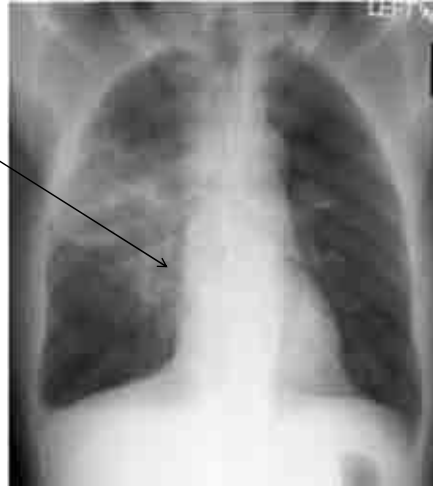
Lung fields continued

- Opacification
 - Size and shape
 - Number and location
 - Alveolar/interstitial
 - Homogeneity
 - Compare with previous films

Consolidation

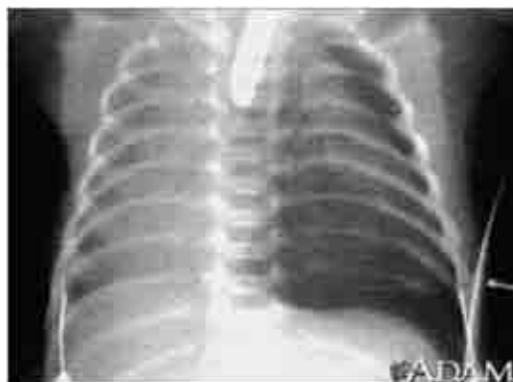
- Lung volume unaffected

Air bronchogram



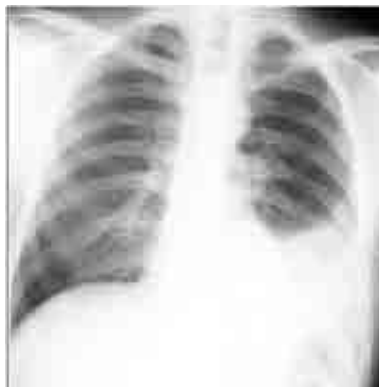Collapse/Atelectasis

- Crowding of ribs
- Tracheal deviation towards collapse
- Raised hemidiaphragm



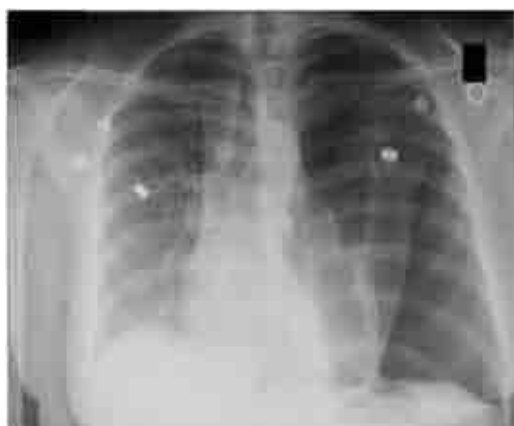
Pleural effusion

- Blunting of cost-phrenic angle
- Displaces mediastinum away from it



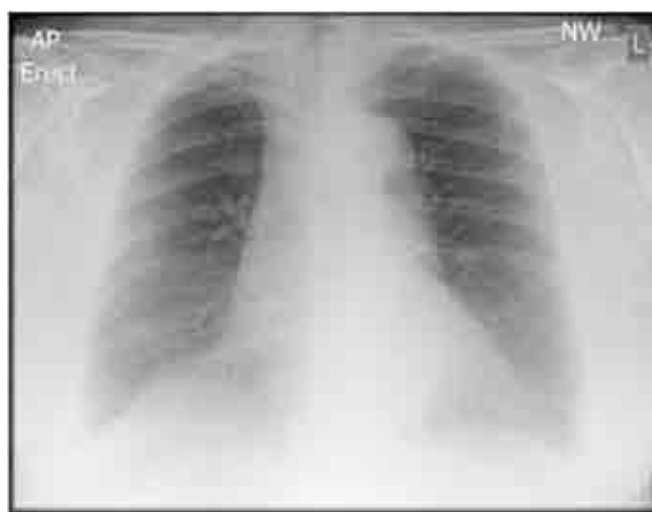
Pneumothorax

- Displaces mediastinum away from it



Systematic review

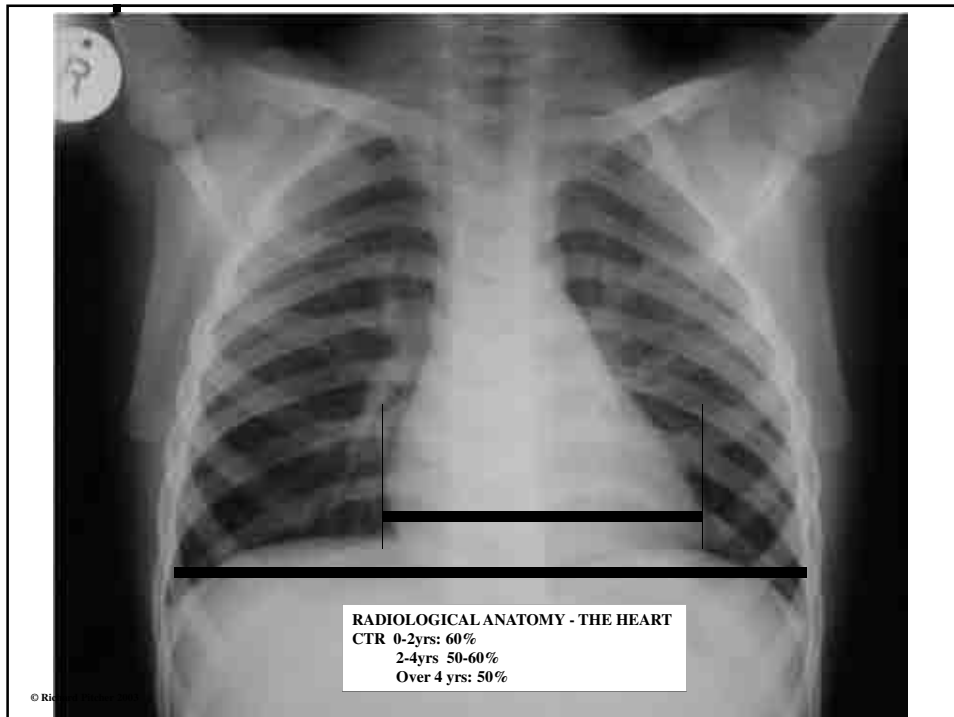
- Trachea, bronchi
- Lung fields
- Mediastinum
- Heart
- Hemidiaphragms
- Foreign body – includes ETT, central lines
- Subdiaphragmatic region
- Other – bones

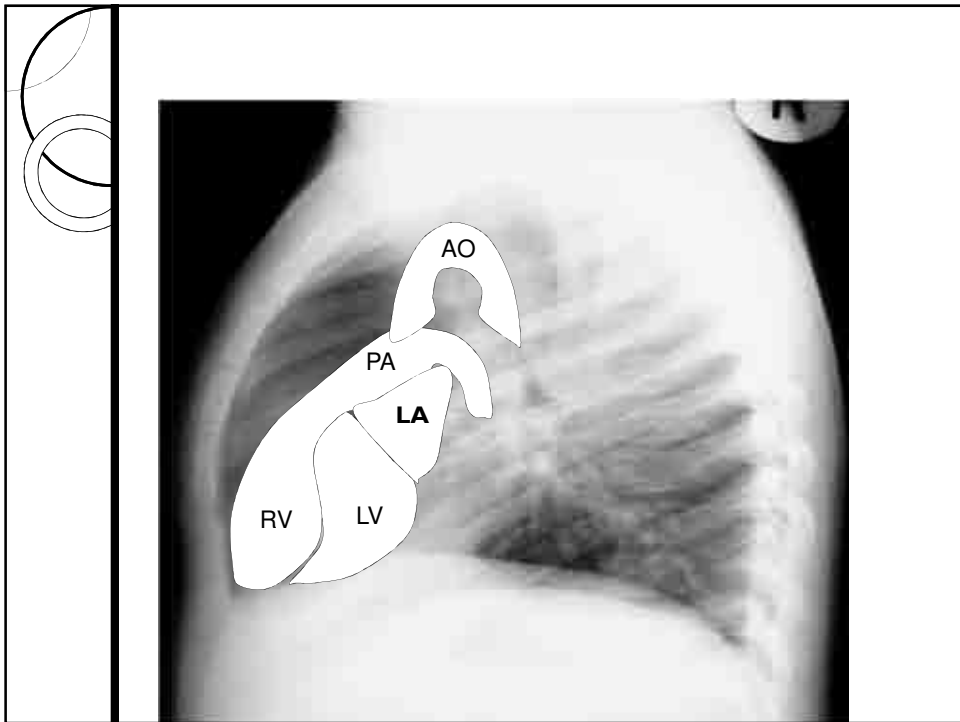
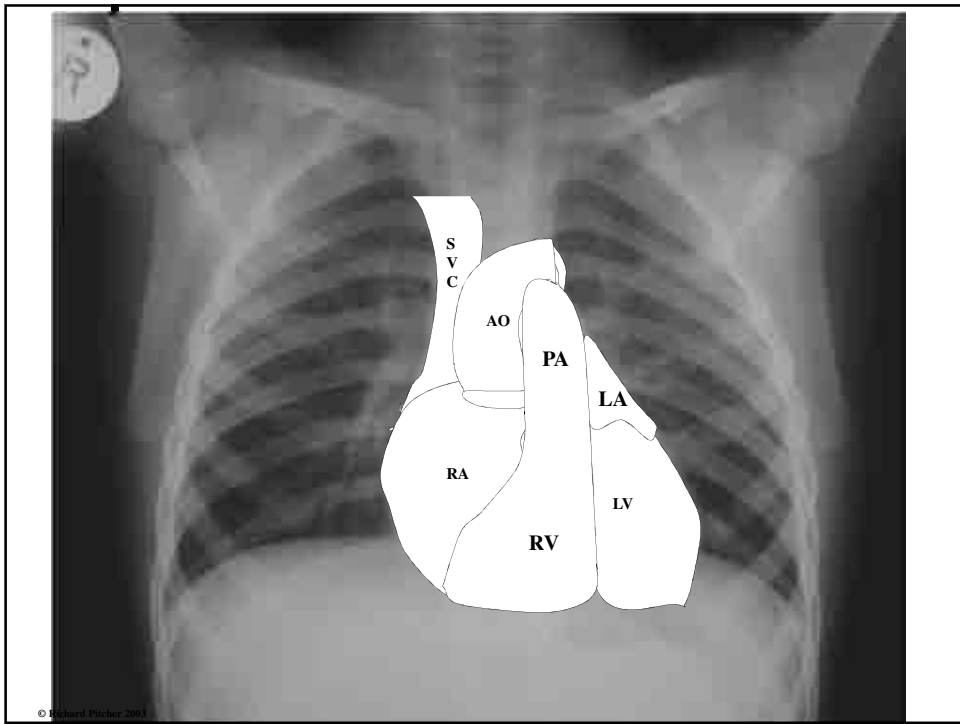


Wide mediastinum

Systematic review

- Trachea, bronchi
- Lung fields
- Mediastinum
- Heart
- Hemidiaphragms
- Foreign body – includes ETT, central lines
- Subdiaphragmatic region
- Other – bones

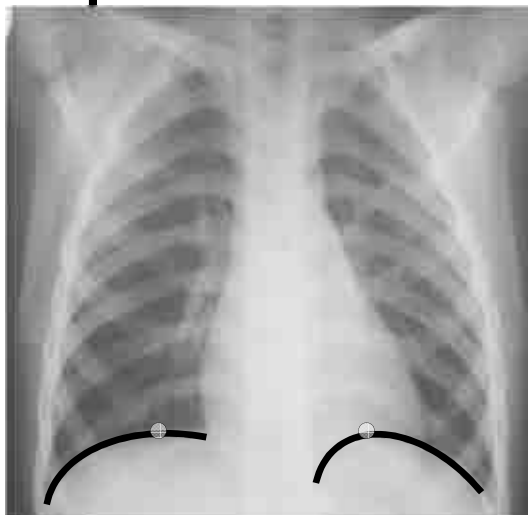




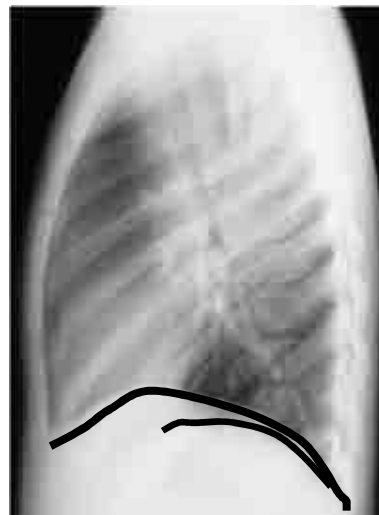
Systematic review

- Trachea, bronchi
- Lung fields
- Mediastinum
- Heart
- Hemidiaphragms
- Foreign body – includes ETT, central lines
- Subdiaphragmatic region
- Other – bones

AP



LAT

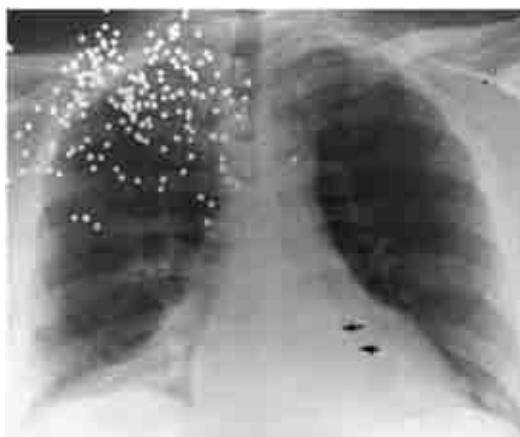


DIAPHRAGM - NORMAL ANATOMY

© Richard Hatcher 2003

Diaphragm continued

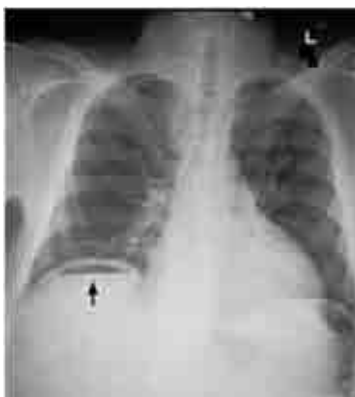- Upward curve of diaphragm



Right lower lobe collapse

Diaphragm continued

- Free air under diaphragm: bowel perforation

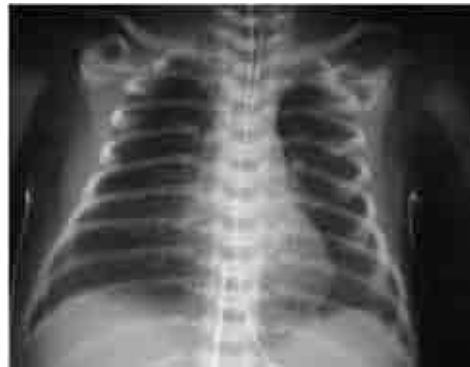

Systematic review

- Trachea, bronchi
- Lung fields
- Mediastinum
- Heart
- Hemidiaphragms
- Foreign body
- Subdiaphragmatic region
- Other – bones

Foreign body

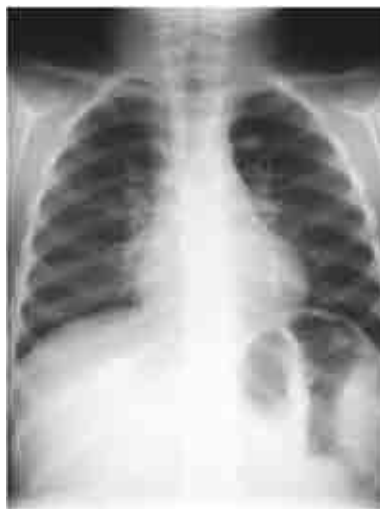- ETT tube
- Intercostal drain
- Central line



Systematic review

- Trachea, bronchi
- Lung fields
- Mediastinum
- Heart
- Hemidiaphragms
- Foreign body – includes ETT, central lines
- Subdiaphragmatic region
- Other – bones

Gas bubble





Systematic review

- Trachea, bronchi
- Lung fields
- Mediastinum
- Heart
- Hemidiaphragms
- Foreign body – includes ETT, central lines
- Subdiaphragmatic region
- Other – bones