

TRAUMA CASE REVIEW

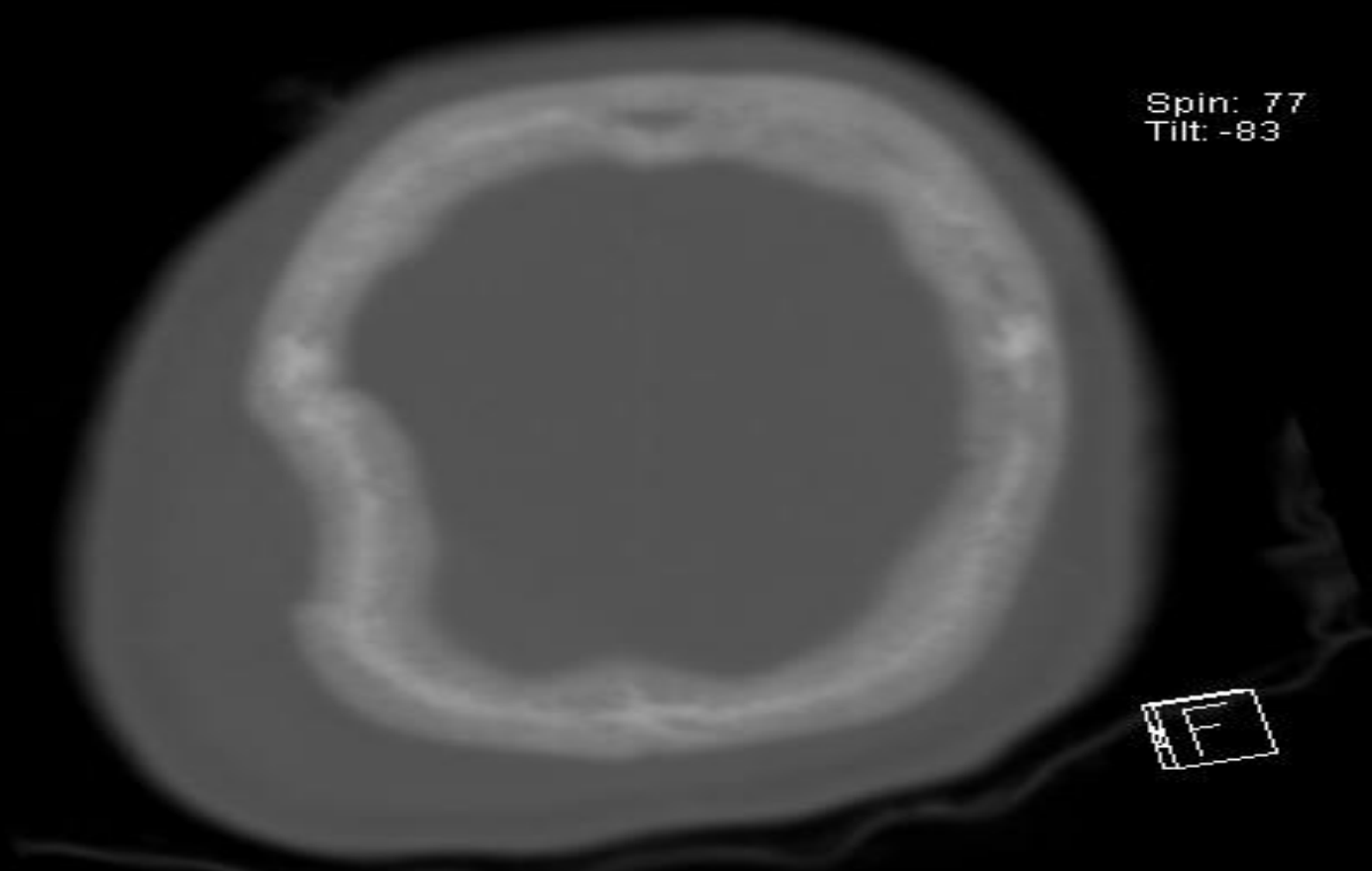
M.F. MKHONZA

DIAGNOSIS ?

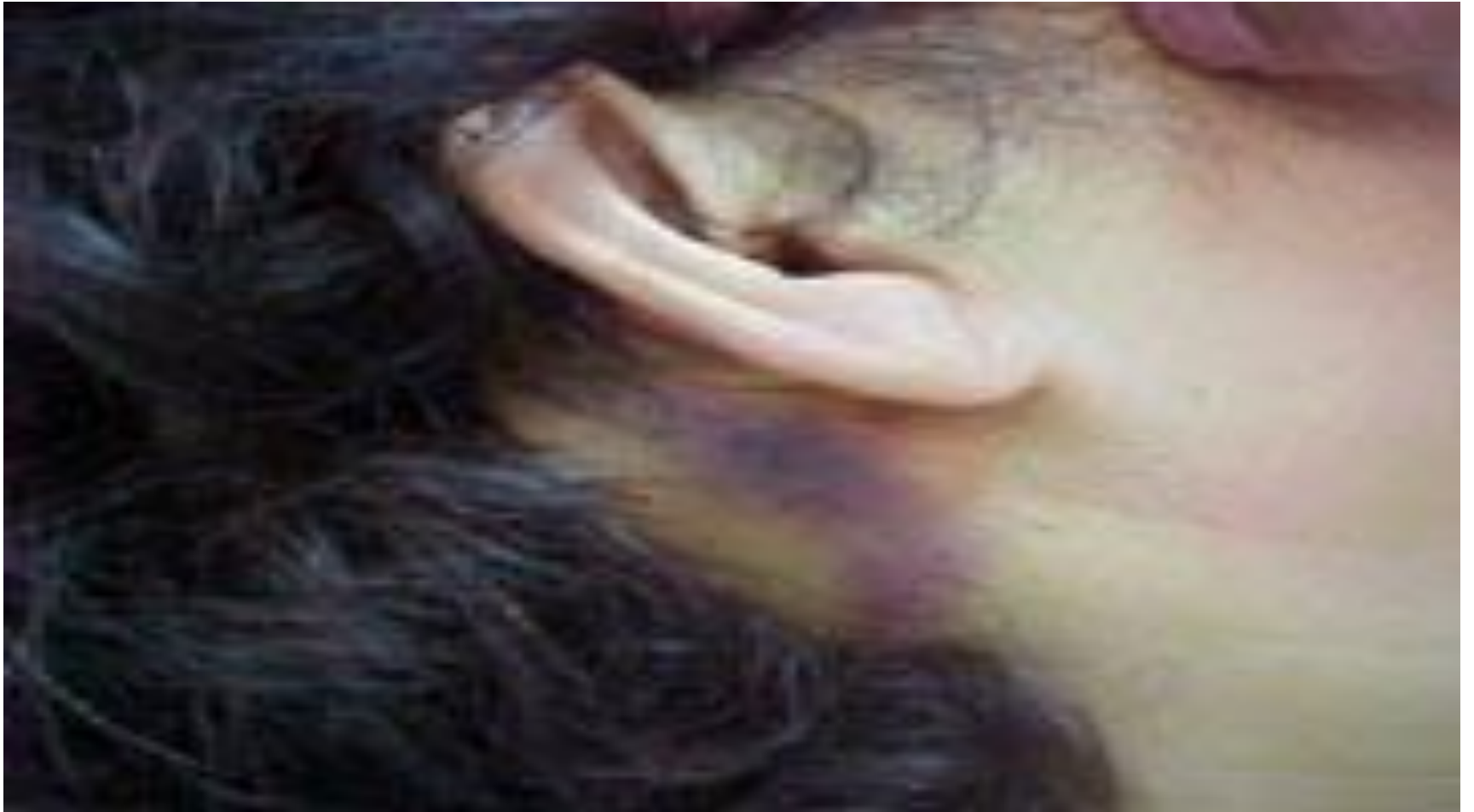MEDCOM RESAMPLED

Spin: 77
Tilt: -83

RF



DIAGNOSIS ?



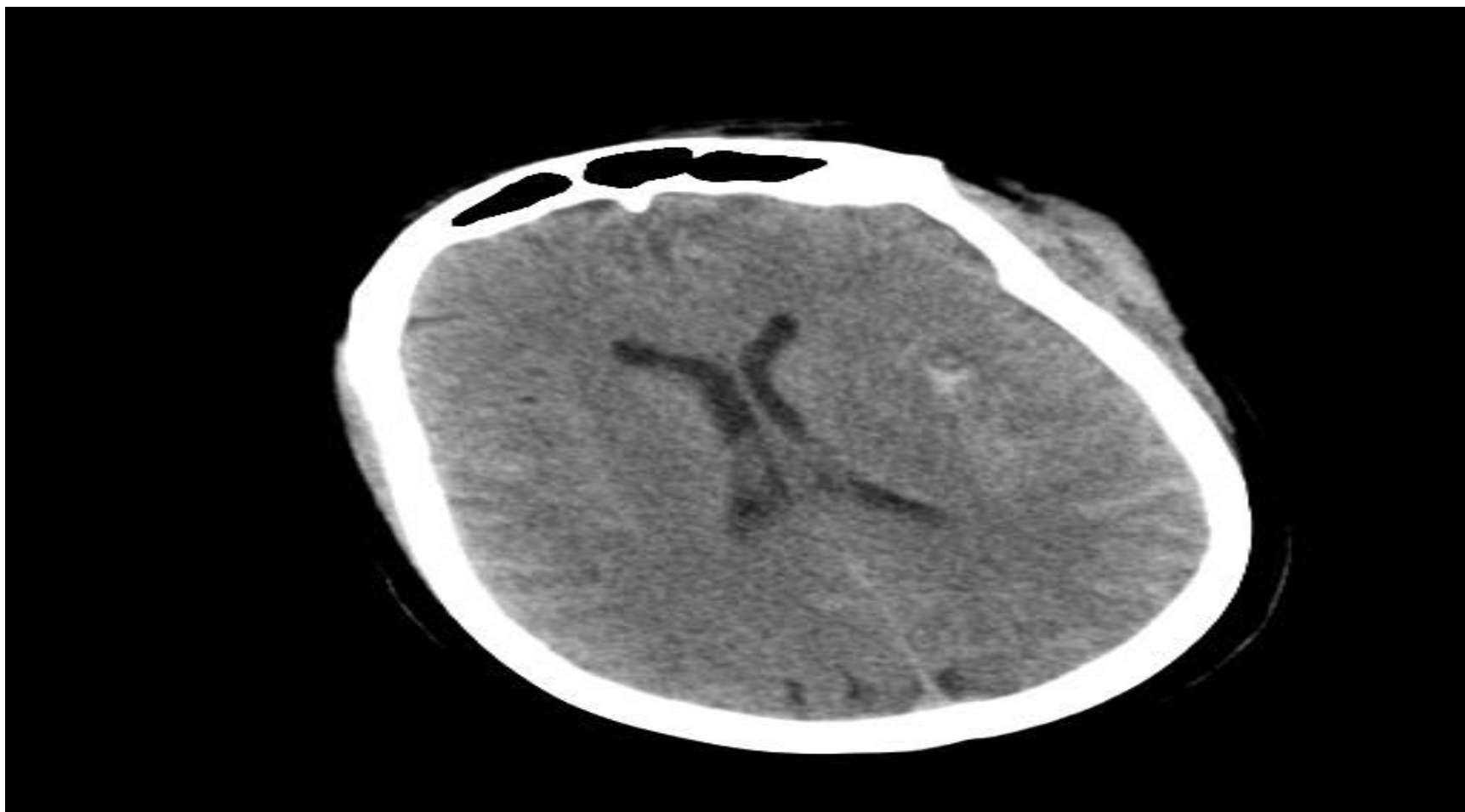
Complications ?

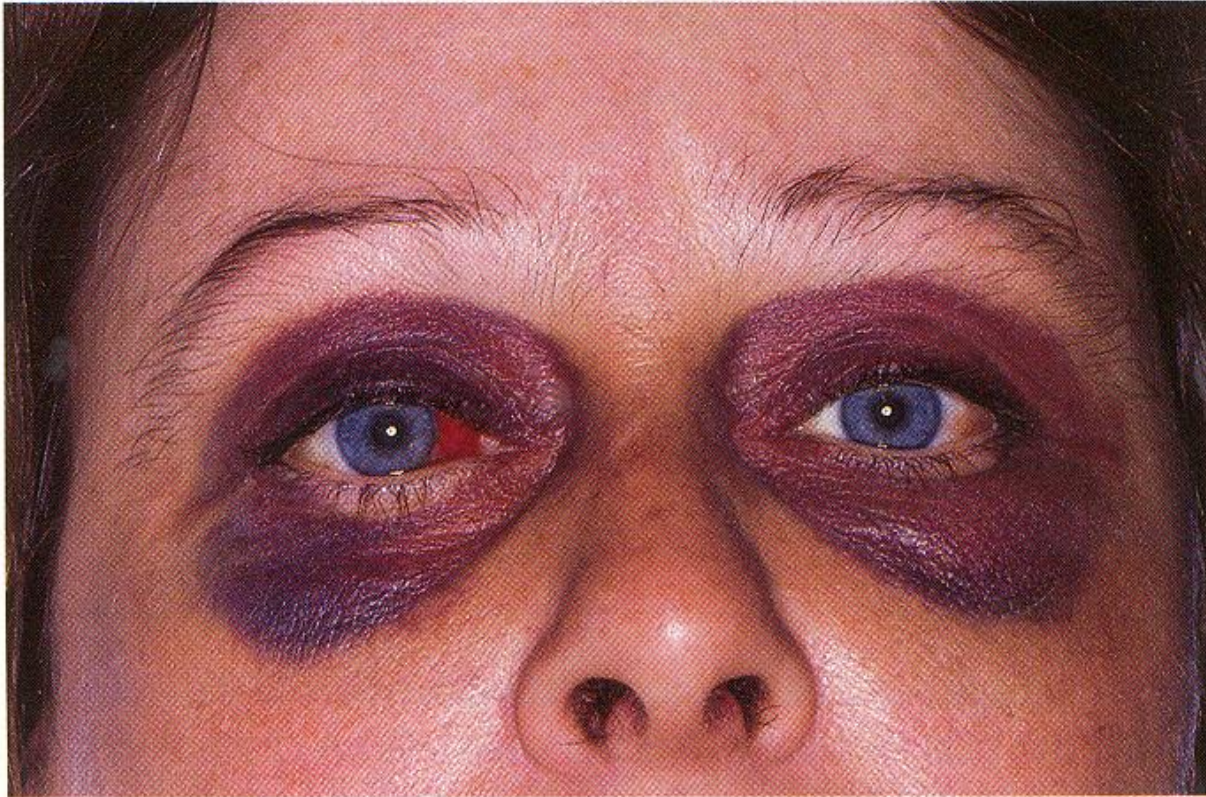

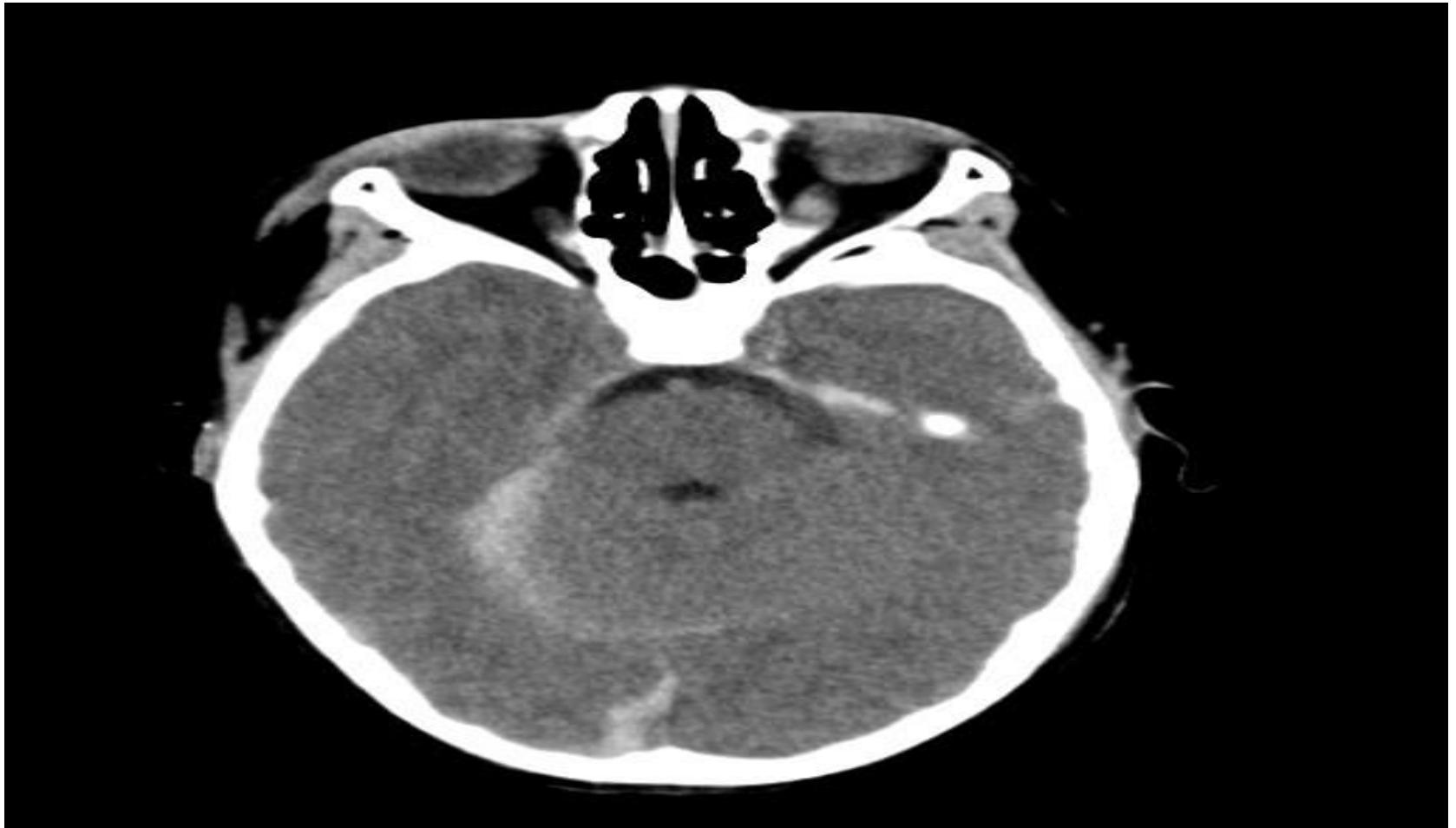
Figure 3.2 Bilateral periorbital ecchymosis (raccoon eyes) indicative of a fracture of the floor of the anterior cranial fossa.

Principles of Neurosurgery. SS Rengachary & RH Wilkins. Wolfe. 1994

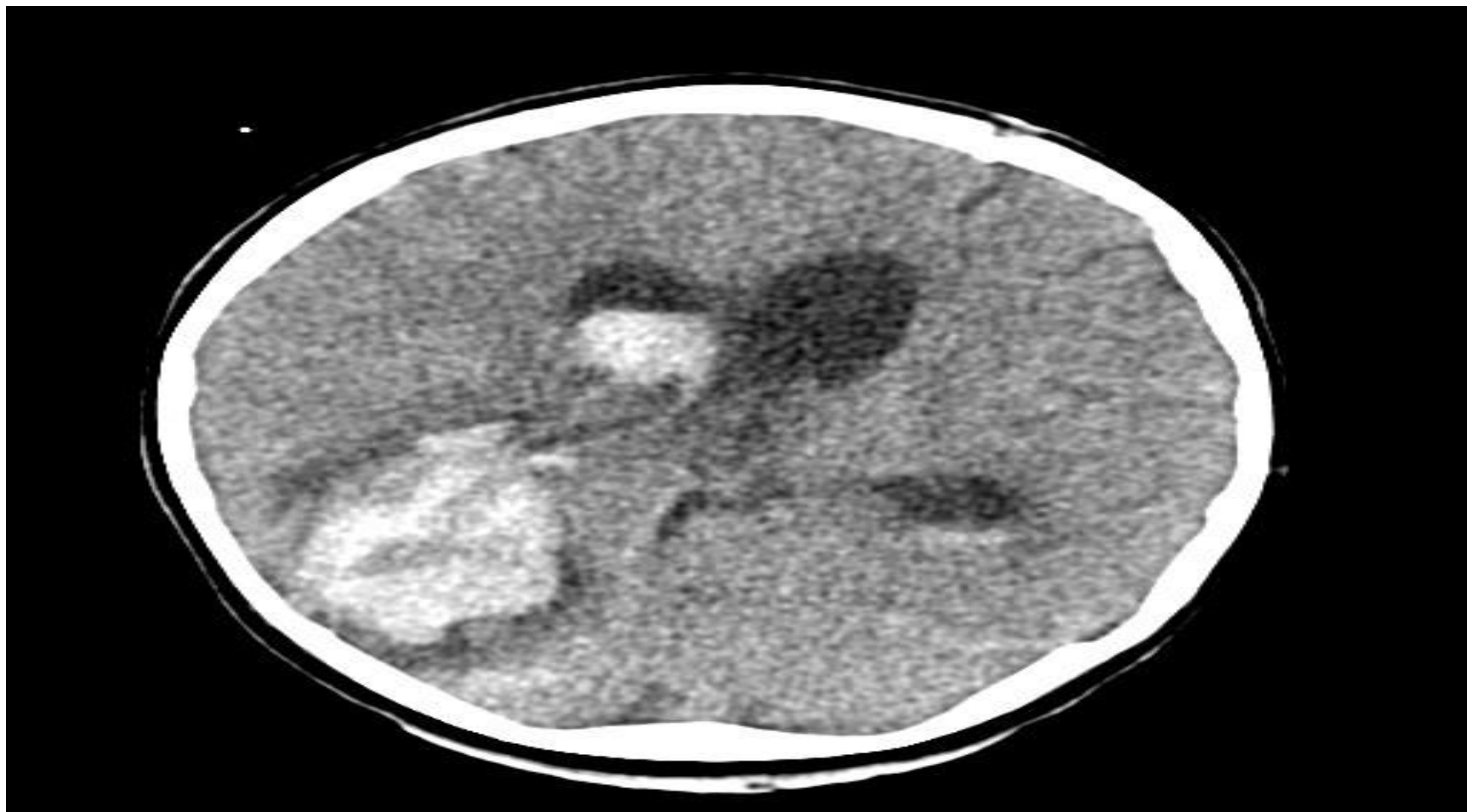
Diagnosis ?



DIAGNOSIS AND COMPLICATION ?



DIAGNOSIS AND COMPLICATION?



CLINICAL SIGNS AND TREATMENT?

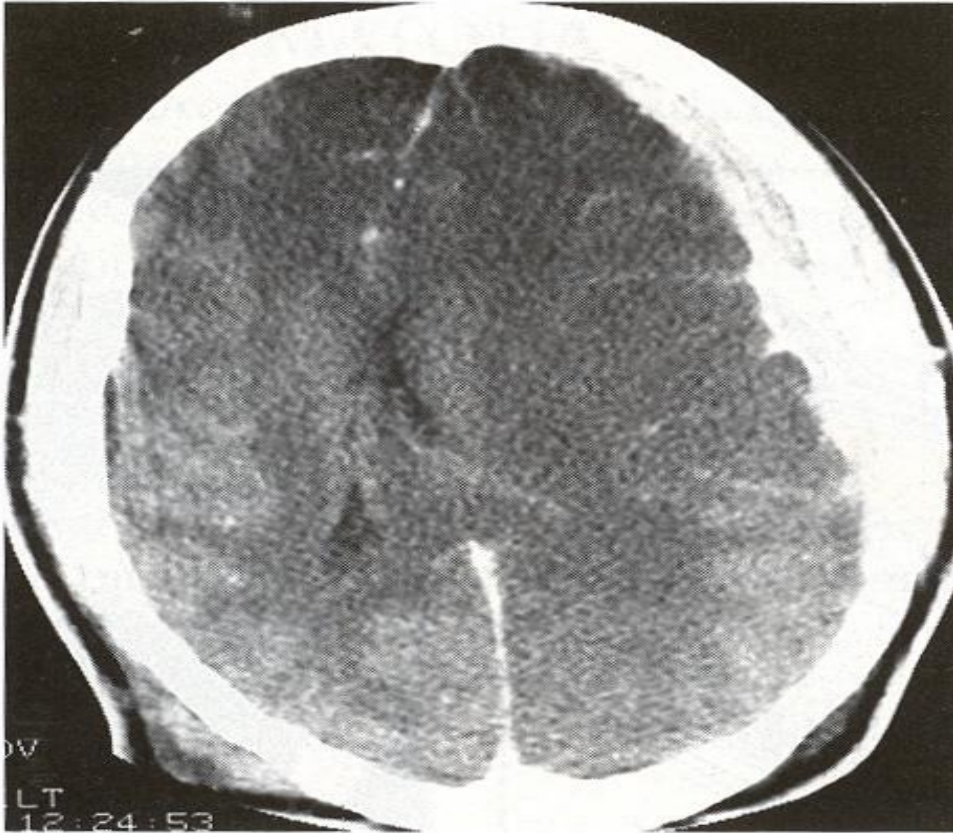
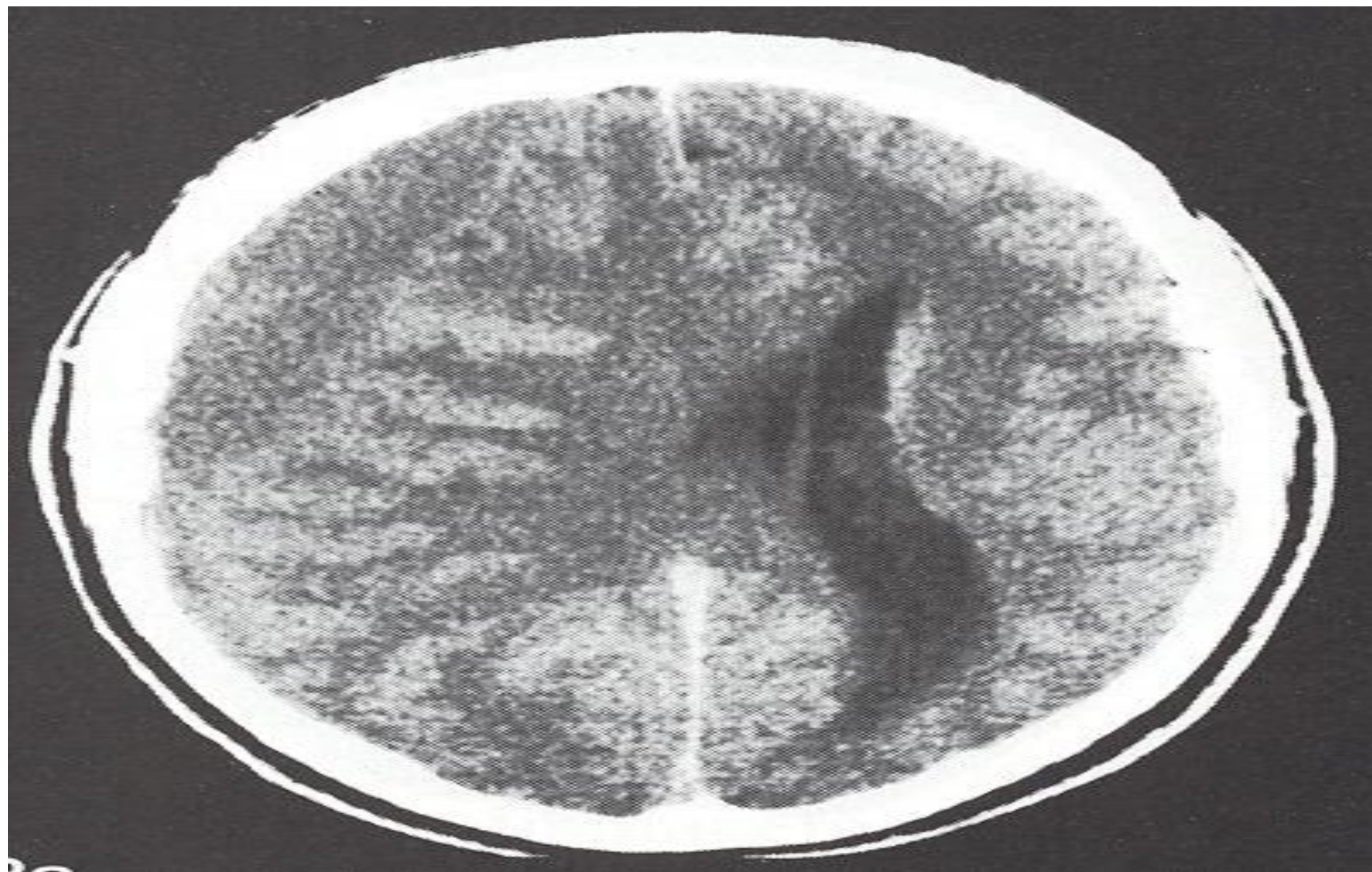
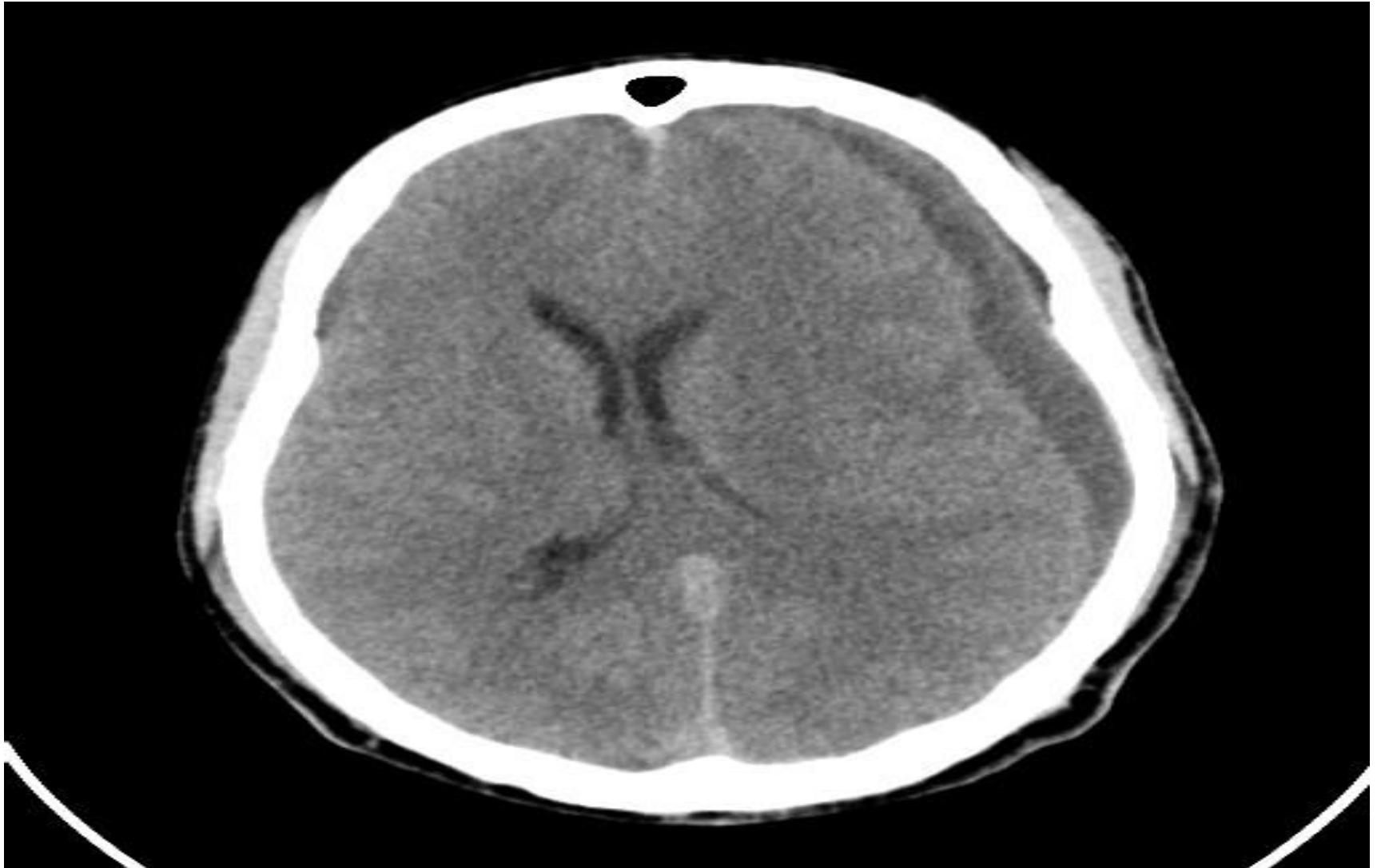
Figure 19.5 Axial CT image of an acute subdural hematoma with associated displacement of the ventricular system.

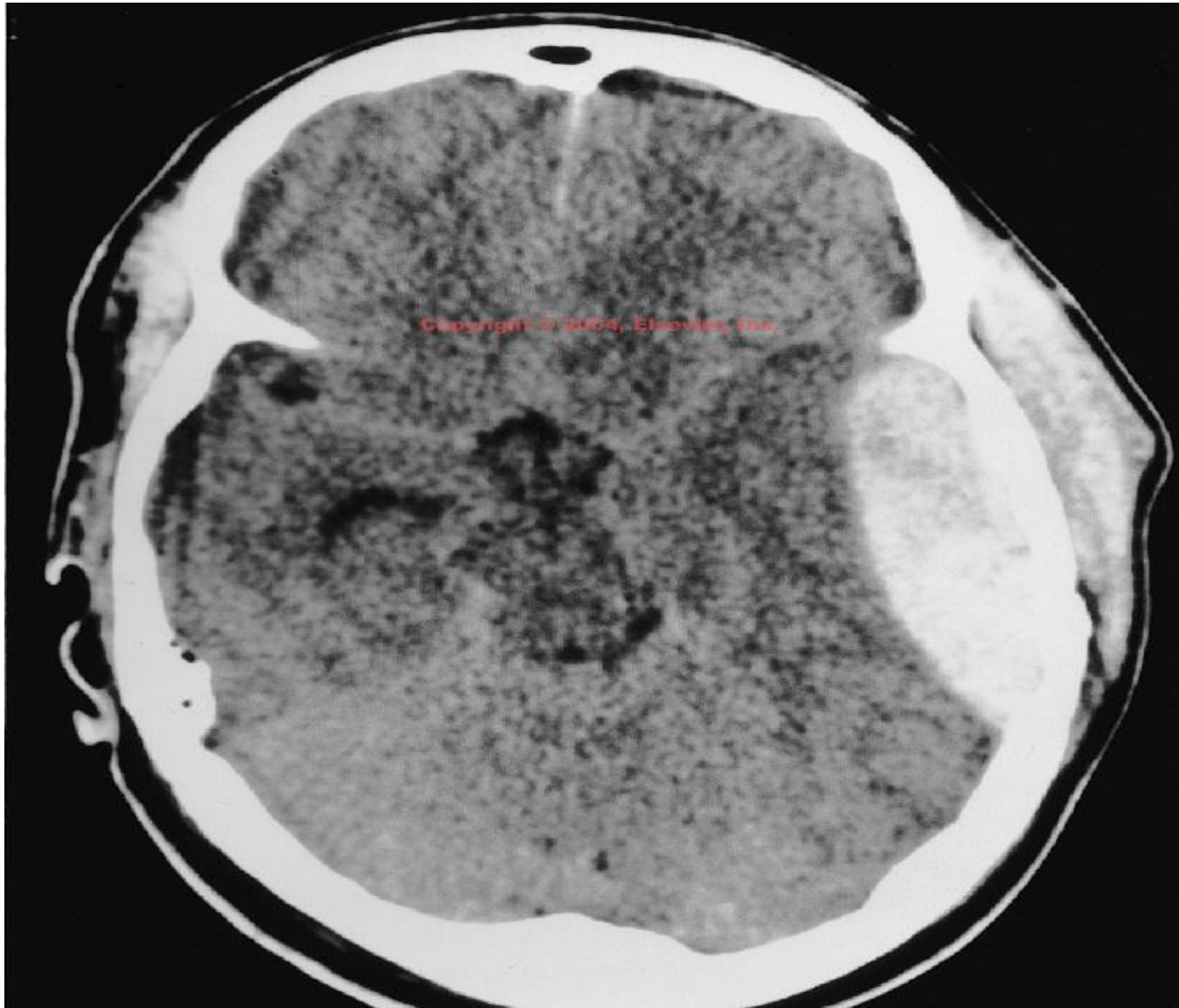
TREATMENT ?



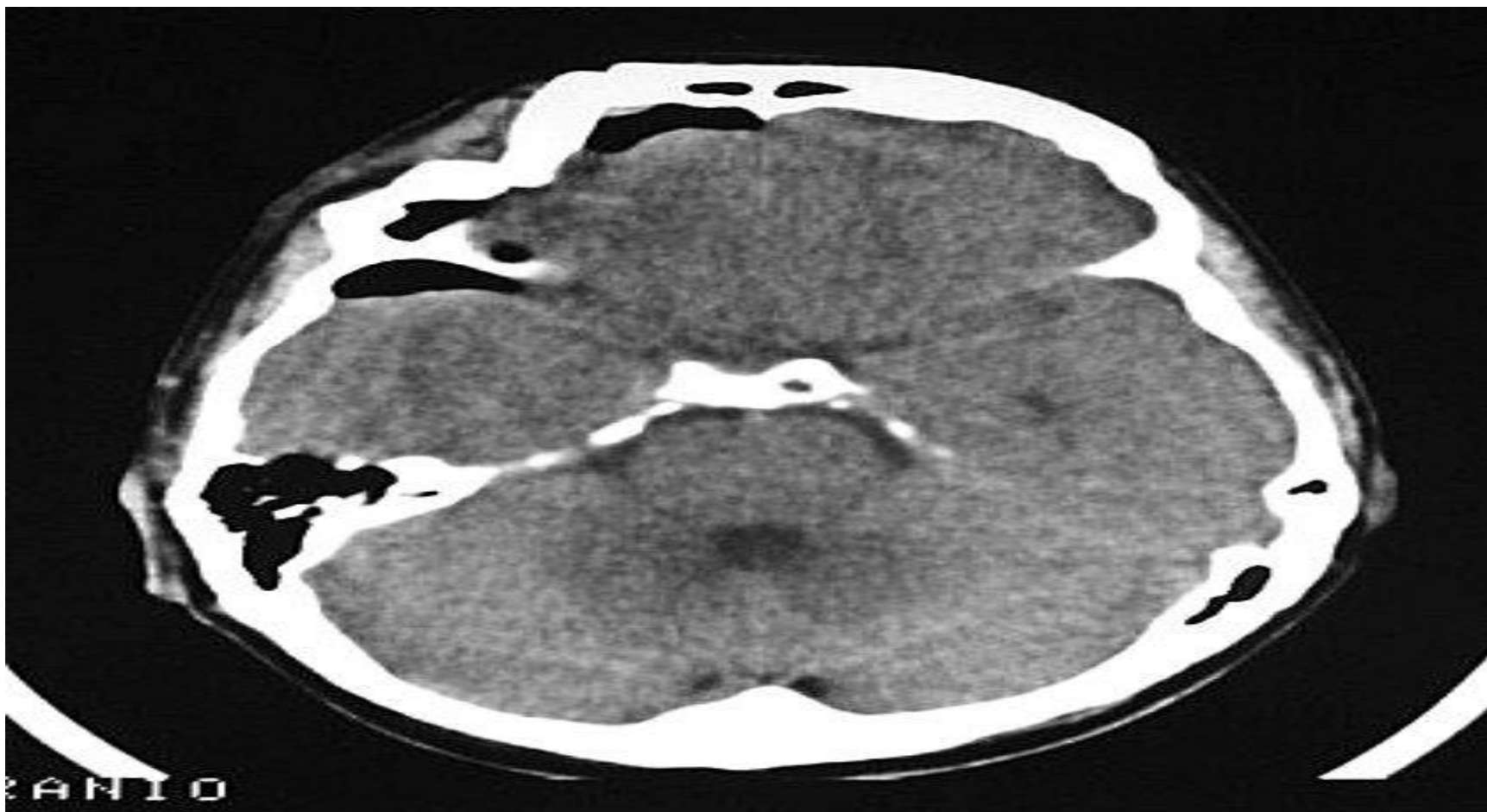DIAGNOSIS ?

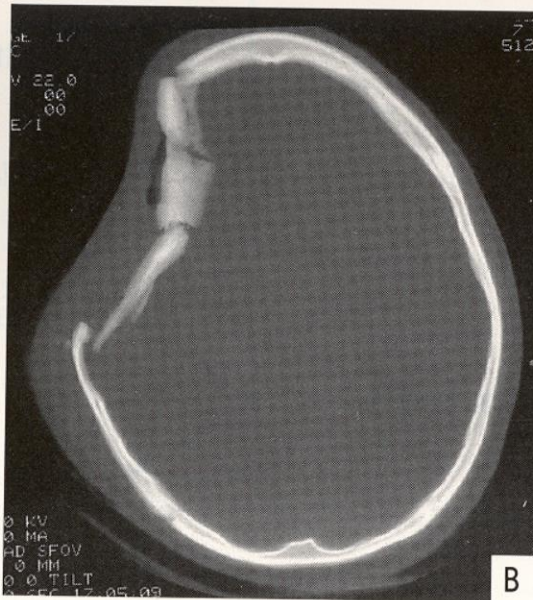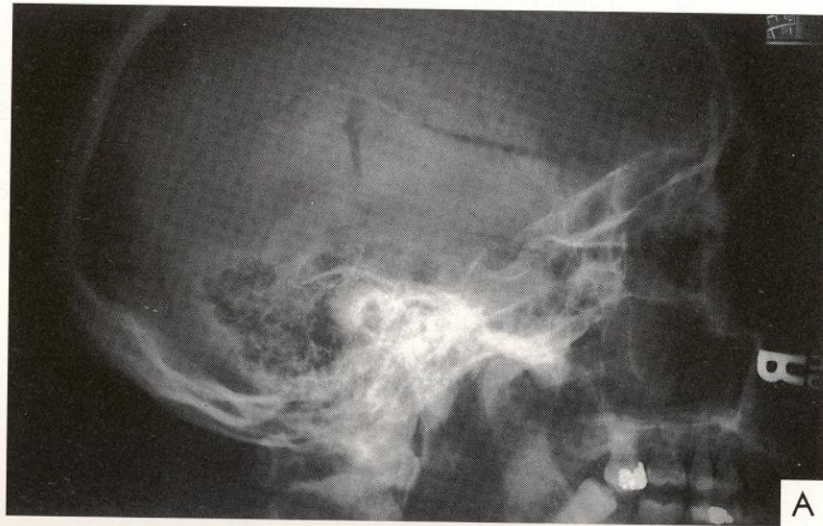


DIAGNOSIS ?



DIAGNOSIS ?





3. What is the diagnosis?

Wat is die diagnose?

QUESTIONS ?